


# Monotube™ Triax™

## Unilateral External Fixation

Operative Technique

Opening Wedge Osteotomy of the  
Tibia for Medial Arthritis of the Knee  
Stephen J. Barr, MD



# Introduction

## Opening Wedge Osteotomy of the Tibia for Medial Arthritis of the Knee

### **Contributing Surgeon**

**Stephen J. Barr, MD**  
Maine Orthopaedic Center, PA  
Portland, ME

This publication sets forth detailed recommended procedures for using Stryker Osteosynthesis devices and instruments. It offers guidance that you should heed, but, as with any such technical guide, each surgeon must consider the particular needs of each patient and make appropriate adjustments when and as required.

A training workshop is required prior to first surgery.

# Introduction

## Preface

High tibial osteotomy (HTO) for the treatment of medial compartment gonarthrosis represents a proven and effective way to relieve pain and improve overall function in the more active patient unsuited for a total knee replacement. Sir Robert Jones (1855-1933) of the Liverpool School, in England, is credited with performing the first HTO distal to the tibial tubercle at the turn of the 19th century. MB Coventry is largely responsible for the popularity of a closing lateral wedge osteotomy in the US, and good results are well documented<sup>1,3</sup>.

Careful selection of patients preoperatively may lead to high success rates of HTO with 80% survival at 10 year follow-up.<sup>10</sup> HTO can result in active patients returning to running and jumping which could lead to failure of a total knee replacement (TKR) quickly.<sup>9</sup> Patients who fail to achieve lasting relief often require TKR to alleviate symptoms. Post HTO TKR has shown slightly poorer results in a number of series when compared with primary TKR<sup>8</sup>, which gives a surgeon pause when recommending HTO to a patient who may well require TKR as a later procedure. Others have found no real difference in the ultimate outcome of the post HTO TKR, but did find some challenges with total knee reconstruction including valgus alignment, patella infera, and decreased bone stock in the proximal tibia<sup>12</sup>.

Recently, promising results have been reported following opening medial wedge hemicallotasis, or distraction osteogenesis, for medial compartment gonarthrosis<sup>2,5,6,7</sup>. Gavriil Ilizarov is credited for underlying the principles of distraction osteogenesis following a corticotomy with the use of the thin wire external fixator which bears his name. Because this is a reconstructive procedure, actually increasing bone stock medially instead of removing a lateral wedge of the tibia, TKR following hemicallotasis may show improved results when compared to the standard closing lateral wedge osteotomies of the tibia.

## Rationale

The drawbacks of lateral closing wedge osteotomies include significant loss of bone in the lateral tibial plateau with shortening of the leg, patella baja secondary to anterior fat pad adhesions, alteration in patellofemoral biomechanics, increased chance of peroneal nerve injury, difficult exposure, constricting skin incisions, retained hardware, and the difficulties inherent in post HTO TKR.

Alternatively, hemicallotasis offers increased bone stock medially on the tibia, less chance for patellar tendon adhesions and patella baja, no fibular impingement, less patellofemoral biomechanical disruption, decreased risk of peroneal nerve injury, a simple technique, longitudinal incisions based medially, and no retained hardware. Also, post hemicallotasis TKR may well be technically easier and demonstrate results similar to primary TKR. Furthermore, this technique usually allows immediate weight bearing as tolerated with pinpoint control of correction. Hemicallotasis adheres to all five of Coventry's guiding principles as outlined in his JBJS article<sup>4</sup>, including that the osteotomy should:

1. Fully correct and, in fact, slightly reverse the varus or valgus deformity
2. Be near the site of the deformity
3. Involve bone that will heal rapidly
4. Allow early motion of the joint and early bearing of weight
5. Present no undue technical difficulties

## Patient Selection

Ideal candidates are patients who wish to maintain an active lifestyle, have reasonable expectations of the outcome, and should be able to both understand the surgery and cooperate with the postoperative care, which requires meticulous daily pin care.

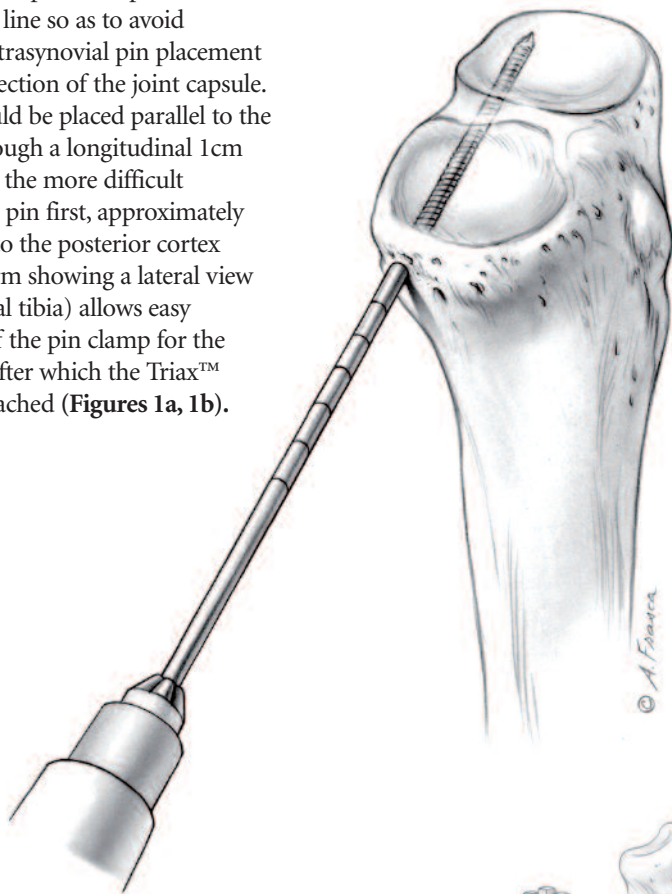
# Operative Technique

## Placement of the Monotube™ Triax™ External Fixator

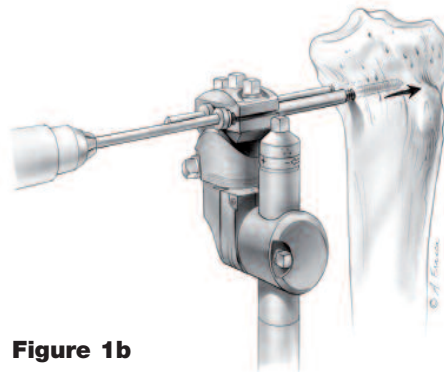
Position the patient supine on a radiolucent table with a tourniquet high on the thigh, prepping the leg free as if for a TKR. C-arm radiography is essential to the procedure.

Pre-assemble the Monotube™ Triax™ device as outlined under “Frame Assembly” on pages 11 and 12 of this technique.

Place the 6.0mm proximal pins 1.5cm from the joint line so as to avoid inadvertent intrasynovial pin placement due to the reflection of the joint capsule. Two pins should be placed parallel to the joint each through a longitudinal 1cm incision. Place the more difficult posteromedial pin first, approximately 1cm anterior to the posterior cortex (with the C-arm showing a lateral view of the proximal tibia) allows easy referencing off the pin clamp for the anterior pin, after which the Triax™ T-clamp is attached (**Figures 1a, 1b**).

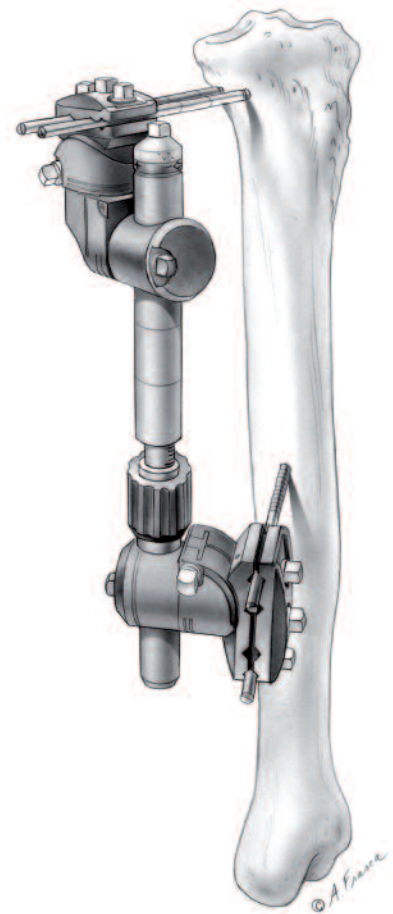


**Figure 1a**  
Orientation of 6.0mm Apex® Pins.



**Figure 1b**

Align the Monotube™ Triax™ Dynamic Tube parallel to the axis of the tibial shaft. The Dynamic Tube should be closed down so the measuring device on the tube measures 5.0mm, with the dynamization collar in the static position, and the biospring adjustment nut set to full tension. Use a surgical pen to mark two longitudinal incisions along the medial slope of the tibial shaft referencing off the pin clamp, and place the two distal 5.0mm pins in an anteromedial to posterolateral direction. Take care to position the standard Triax™ pin clamp anterior to the Dynamic Tube so as to avoid inadvertent extension of the osteotomy during hemicallotaxis. Tighten all nuts on the Dynamic Tube and pin clamps (**Figure 2**).

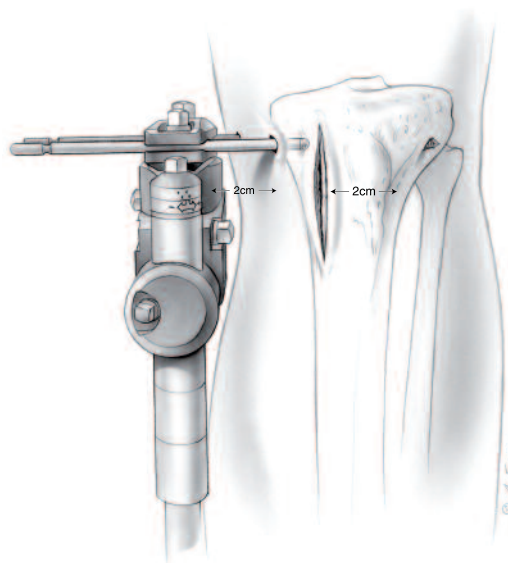


**Figure 2**  
Alignment of Monotube™ parallel to tibial axis.

# Operative Technique

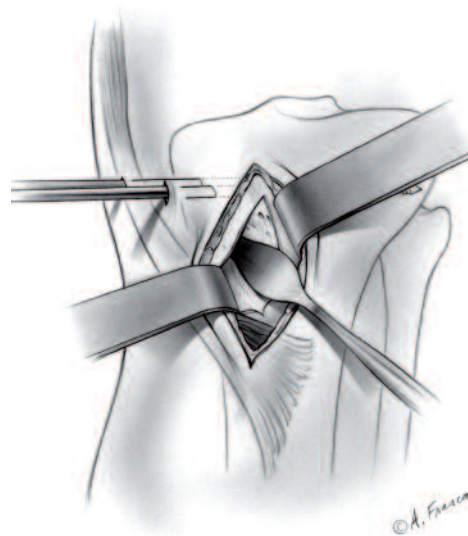
## Osteotomy

Incise the skin longitudinally 2cm medial to the tibial tubercle to a length of approximately 4cm. Preserve and retract the lateral cutaneous branch of the saphenous nerve if possible (**Figure 3**). A distance of 2cm should be maintained between the skin and the pin clamps to allow for easier pin care and space for postoperative swelling.



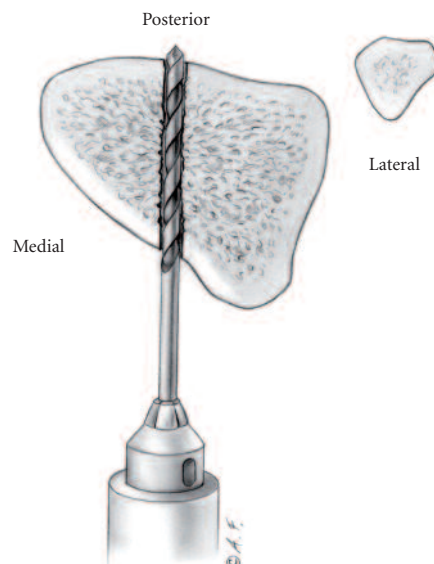
**Figure 3**

Sharply incise the periosteum longitudinally just above and lateral to the pes anserinus and dissect subperiosteally posteriorly under the hamstring tendons and anterolaterally out to the tibial tubercle leaving the periosteum intact as one sleeve. Use a curved Chandler retractor to retract the soft tissues (**Figure 4**).



**Figure 4**

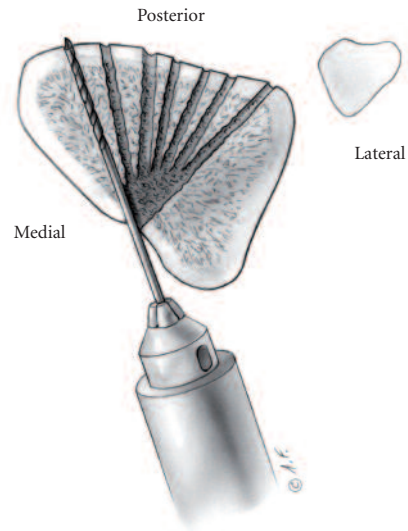
Under C-arm guidance, drill a single hole paralleling the joint surface using a 4mm bit (**Figure 5a**). The location should be a minimum of 1cm below the pins and located in the metaphyseal area of the tibia. Usually this passes through some of the distal fibers of the deep medial collateral ligament.



**Figure 5a**

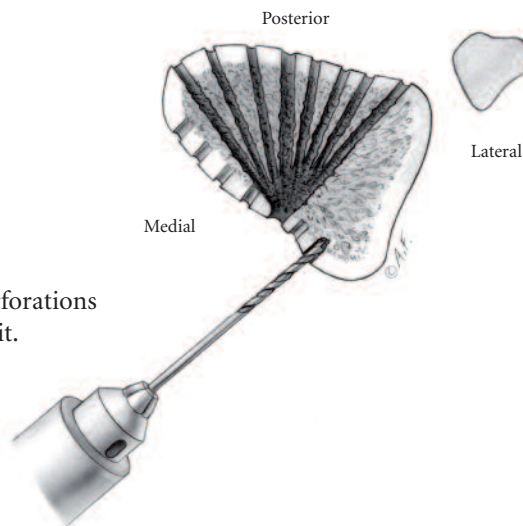
# Operative Technique

Change the 4.0mm drill bit to a 2.8mm drill bit. With the goal of leaving the lateral 30% of the tibial cortex intact, begin drilling a series of holes in the posterior tibial cortex, each parallel to the joint surface, using the previously made 4.0mm perforation as a window (Figure 5b). An oscillating drill may be used to reduce the chance of soft tissue damage.



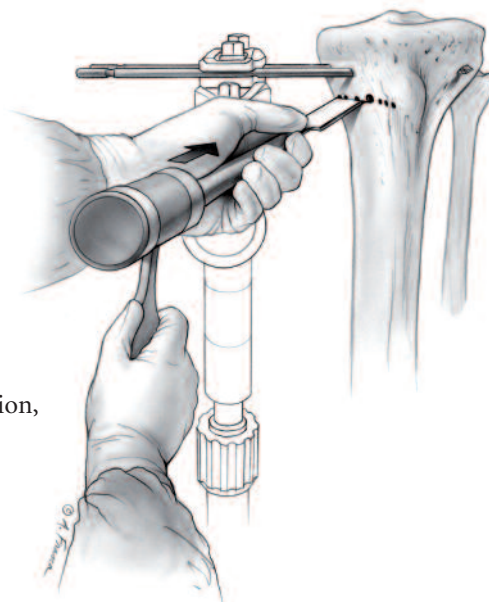
**Figure 5b**

Finish perforating the remaining intact anterior tibial cortex under direct visualization parallel to the joint surface and continuing in a lateral direction through the tibial tubercle and the distal insertion of the patellar tendon fibers (Figure 6).



**Figure 6**  
Anterior cortex perforations with 2.8mm drill bit.

Distract the Dynamic Tube 2-3mm to pre-stress the osteotomy site. Carefully connect the drill holes using a 1/2 inch straight osteotome and mallet, taking care not to plunge into the posterior soft tissues (Figure 7). Often one will feel or hear an audible crack as the osteotomy is completed.



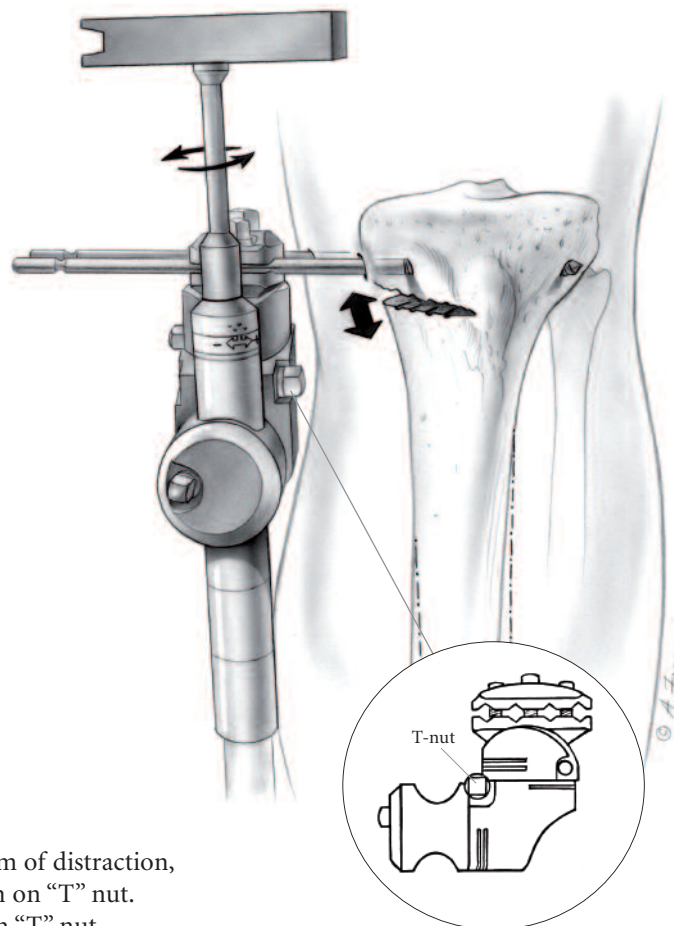
**Figure 7**  
After 2-3mm of distraction, connect drill holes with an osteotome.

# Operative Technique

## Distraction

Under C-arm guidance the Monotube™ Triax™ fixator is slowly distracted, gradually opening up the medial osteotomy (**Figure 8**). After the fixator measures 0.5 to 1.0cm of distraction release the tension on the “T” nut. This will allow the pin-fixator subtended angle to relax with respect to the opening osteotomy causing a force vector more suited to opening the osteotomy like a book, and not straight longitudinal distraction. Retighten the “T” nut in its new position and continue distraction until the desired correction is obtained both clinically and radiographically. One can palpate the femoral head and evaluate the correction off a plumb line from the hip to the foot, or use a bovie cord and C-arm.<sup>11</sup>

Pauses throughout the distraction process allow the lateral cortex some time to bend and undergo plastic deformation rather than fracturing. It is important to make sure the entire correction needed can be obtained intraoperatively, and that the final distraction measurement is noted and documented. Release tight skin around pin sites as necessary. Depending on the distance of the fixator from the center of rotation of the tibia, the preexisting varus of the tibial shaft, and the size Monotube™ Triax™ System used, the distraction distance needed will vary. After completion of the correction, the fixator is compressed down to the original starting point closing the osteotomy site. Do not release the “T” nut at this time; allow the pins to bend in reverse as the monotube is compressed. Dress the pin sites with cotton gauze and place an ace compression bandage to reduce postoperative swelling.



**Figure 8**  
After 0.5-1.0cm of distraction,  
release tension on “T” nut.  
Then retighten “T” nut.

# Postoperative Care

Most of these cases may be done in an outpatient surgical setting with follow-up 5-7 days postoperatively. This is ample time to allow the fracture hematoma to consolidate prior to beginning distraction osteogenesis. A patient instruction form, included at the end of this technique, can be photocopied and individualized for the patient by the surgeon with specific instructions and phone number.

## Pin Care

Pin care remains crucial to the success of the procedure and avoidance of the main complication, pin site infection. Twice a day pin care with 1/2 saline 1/2 hydrogen peroxide solution soaked Q-tips coupled with one warm shower a day to reduce the risk of infection. During showering an old soft bristle toothbrush with soap is helpful to scrub the interface between the pin and skin. Direct application of cotton gauze pads around each pin site followed by an elastic compression bandage works well to aide in debridement. Patients should be cautioned that infections usually develop when the skin is allowed to heal around and seal off the pin, thus promoting subcutaneous abscesses and possible deep infection.

## Hemicallotaxis

The patient is given a wrench to distract the Dynamic Tube the appropriate number of turns so as to arrive at the desired correction over a two week period. This usually means one and a half turns a day, as one full turn equals 1mm on the Dynamic Tube. The patients can break this up into a full turn in the morning and one half turn at night. Follow-up radiographs at three weeks post-operatively should confirm appropriate correction. Patients should be cautioned that distraction may be painful, producing a deep “toothache” type of pain which should resolve after an hour or so. If this becomes too painful the patient can decrease the number of turns a day, but this will result in prolonging the time until full correction. Four weeks following completion of correction, release the dynamization bolt to the number one setting from the zero setting. This will allow micromotion at the osteotomy site and hasten bony union. Four weeks after dynamization, or 8-10 weeks following the operative procedure, a final radiograph is taken. Early union should be apparent at the osteotomy site. The fixator may then be removed in the operating room under intravenous sedation, or under intramuscular medication in the office. A small wick of cotton gauze or tape should be placed deep into the existing pin site after removal of each of the four pins. The dressing may be removed 48 hours later and pin site care resumed until the pin sites are fully healed. This will help to avoid premature closure of the wound and possible subcutaneous infection.

## Physical Therapy

Weight bearing status will depend on the type of surgery performed. If biological regenerative techniques such as microfracture, osteochondral autograft transfer, or meniscal allograft replacement are used in conjunction with hemicallotaxis, weight bearing may be partial for 6 weeks, otherwise weight bearing as tolerated with crutches may be instituted from the start. Range of motion exercises and quadriceps muscle strengthening supervised by a therapist are helpful. A home continuous passive motion machine (CPM) is not usually needed.

# Operative Technique

## Fixator Assisted Opening Wedge Osteotomy

### Using Autologous Iliac Crest Bone Graft

Instead of utilizing hemicallotaxis to create new medial tibial bone stock and realign the anatomic axis to an overall valgus position, two wedges of iliac crest autologous graft may be placed at the time of the operative osteotomy. This obviates the need for long term use of the Monotube™ Triax™ fixator and may reduce the chance of deep infection from the pin sites. Its drawbacks include the need for a second incision to harvest the bone graft, supplemental medial hardware, and the need for protected weightbearing for 6-8 weeks as the graft begins to consolidate. The technique proceeds exactly as above, but when the osteotomy site is distracted appropriately to provide adequate clinical correction of the tibial anatomic axis into valgus, two tricortical wedges of iliac crest graft are placed and impacted in with a bone tamp medial to lateral. The grafts are positioned so as to support the osteotomy with the outer cortex of the grafts flush with the osteotomized cortex of the tibial metaphysis. Voids in the tibial osteotomy site can be packed with currettings of cancellous bone graft. After the distraction is released on the Dynamic Tube, supplemental fixation may be used to hold the osteotomy site closed down and the grafts in place on the medial side. A small three hole semi-tubular plate from a standard small fragment set is usually adequate, fixing the proximal hole with a fully threaded 6.5 cancellous screw, and the distal hole with a large fragment 4.5 cortical screw. The mechanical advantage of the Monotube™ Triax™ System allows a more controlled osteotomy and the added advantage of an intact lateral cortex and periosteal sleeve. Assessment of clinical correction is easier, and one can measure the thickness of tricortical graft needed more precisely.

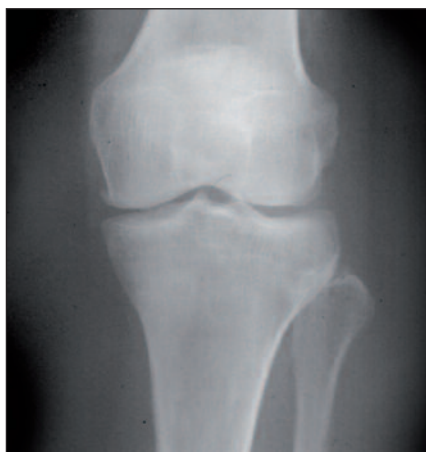Contra-indications include a patient who is unable to properly care for the pin sites of the fixator or patients prone to deep infections, such as those with diabetes. Patients may also be given the choice of either opening wedge technique. Results at two year follow-up have shown no difference in union rate, overall correction, rate of complication, or final result as measured prospectively with the SF-36 outcomes scores between opening wedge osteotomy utilizing hemicallotaxis or fixator assisted with interpositional tricortical iliac crest graft.<sup>13</sup>

# Clinical Cases

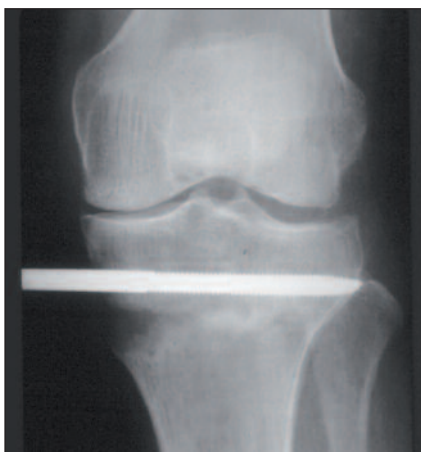The radiographs below demonstrate pre-operative, post-operative, and 12 month follow-up of opening wedge osteotomy of the tibia using both hemicallostasis and tricortical iliac crest graft.

## Case A

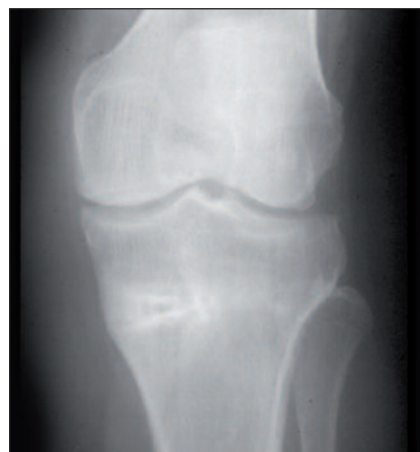42 year-old female with varus gonarthrosis treated with hemicallostasis technique.



**Pre-Operative**



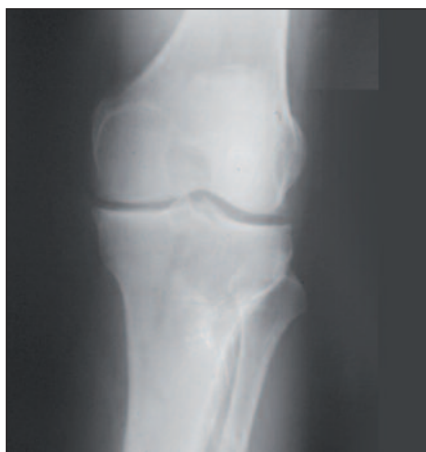**Post-Operative**



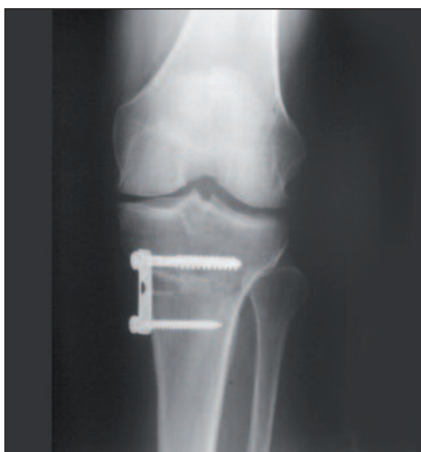**1 Year Follow-up**

## Case B

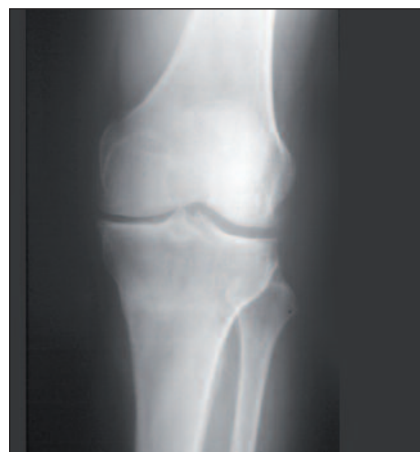51 year-old male diabetic with varus gonarthrosis treated with Monotube™ Triax™ for opening wedge distraction and tricortical iliac crest graft. Ancillary fixation obtained with semi-tubular plate.



**Pre-Operative**


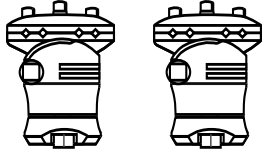
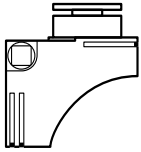



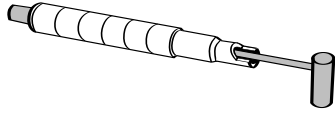
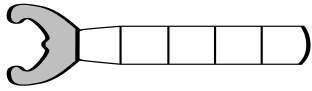
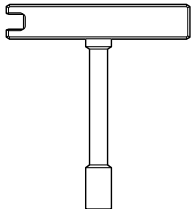


**Post-Operative**



**1 Year Follow-up after hardware removal.**

# Ordering Infomation

| REF   | Description  |
|---|--|
| <b>For Hemicallostasis, the typical setup includes:</b>                             |  |
| <b>Components</b>   |  |
|    | 5150-0-470 Monotube™ Triax™ Dynamic Tube - Blue (1)  |
|    | 5150-3-070 Monotube™ Triax™ Pin Clamp - Blue (2)   |
|    | 5150-4-070 Monotube™ Triax™ T-Adaptor - Blue (1)   |
|    | 5020- Series Ø 5mm Blunt Apex® 1/2 Pins (2 each)<br>5019- Series Ø 6mm Blunt Apex® 1/2 Pins (2 each)<br>OR<br>5018- Series Ø 5mm Self-Drilling Apex® 1/2 Pins (2 each)<br>5021- Series Ø 6mm Self-Drilling Apex® 1/2 Pins (2 each) |
| <b>Instruments</b>  |  |
|  | 5057-5- Series Ø 5mm Drill Sleeve Assemblies for 5mm 1/2 Pins - (2 each)<br>5057-6- Series Ø 6mm Drill Sleeve Assemblies for 6mm 1/2 Pins - (2 each)   |
|  | 5235-x-824 Series Ø 4.0mm Drill Bits 4mm & 2.8mm (2 each)<br>5255-x-250 Series Ø 2.8mm Drill Bits 4mm & 2.8mm (2 each)   |
|  | 5150-9-270 Monotube™ Triax™ Torque Wrench - Blue (1)   |
|  | 5150-9-120 Monotube™ Triax™ Dynamization Wrench - Blue (1)   |
|  | 5054-3-005 T-Handle Wrench (1)   |

# Frame Assembly

## Monotube™ T-Adaptor Assembly

Standard Monotube™ Triax™ Clamps can be converted to T-clamps utilizing the T-adaptor.

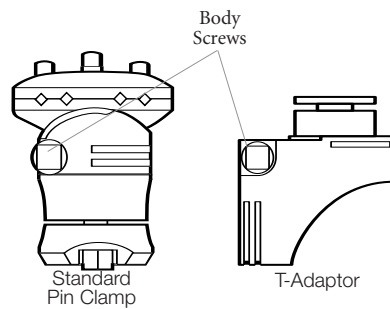
### Assembly Instructions

1. Select the T-adaptor and matching Standard Pin Clamp (**Figure 9**).
2. Remove body screw and compression sleeve for T-adaptor with Monotube™ wrench (**Figure 10**).
3. Remove body screw and compression sleeve from Standard Pin Clamp. Separate pin connector from the tube coupling (**Figure 11**).
4. Insert tube coupling into the T-adaptor and replace compression sleeve (**Figure 12**). Body screws should be introduced through the recessed portion of the clamp until fully seated and finger tight.
5. Insert pin connector onto T-adaptor and replace compression sleeve (**Figure 13**). Body screws should be introduced through the recessed portion of the clamp until fully seated and finger tight.

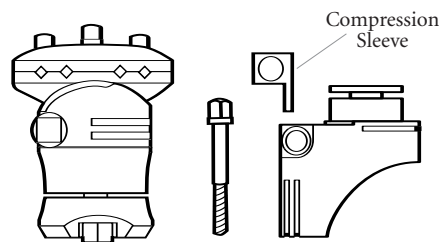
NOTE: Body screws and compression sleeves are exactly alike and will fit in either position. However, if body screws are not introduced from the recessed side of the clamp, they will not fully seat. In addition, the T-adaptor should always be connected to the tube coupling before the pin connector.

6. The T-clamp assembly is now ready for use (**Figure 14**).

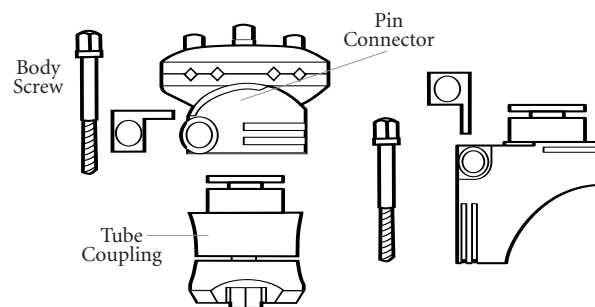
**Fig 9**



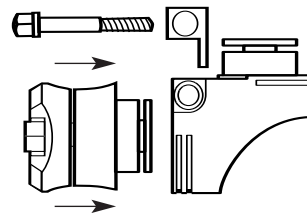
**Fig 10**



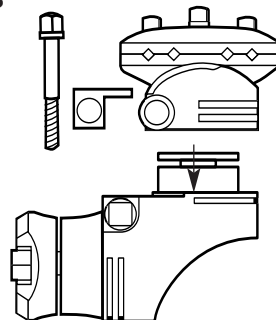
**Fig 11**



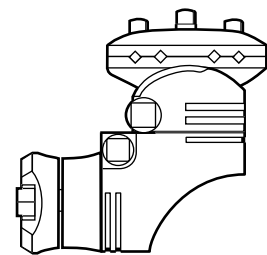
**Fig 12**



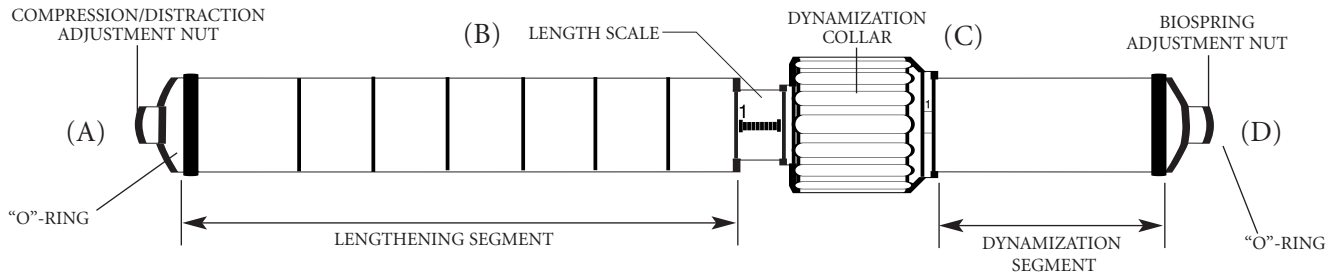
**Fig 13**



**Fig 14**



# Frame Assembly



## Monotube™ Triax™ Dynamic Tube

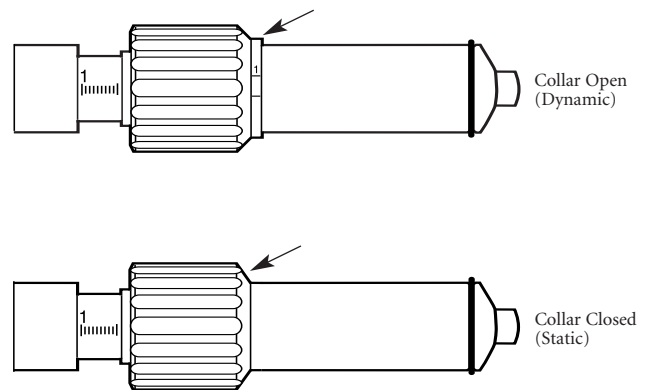
Dynamic Tubes include an internal compression/distraction mechanism which is useful in lengthening procedures and to “fine-tune” fracture reductions. The long portion of the tube is referenced as the Lengthening Segment. The shorter portion is called the Dynamization Segment, and includes two adjustable dynamization features: biocompression and variable biospring.

Turn compression/distraction adjustment nut (A) to display 5mm of distraction on tube (B). Close dynamization collar (C) to static position (Figure 15).

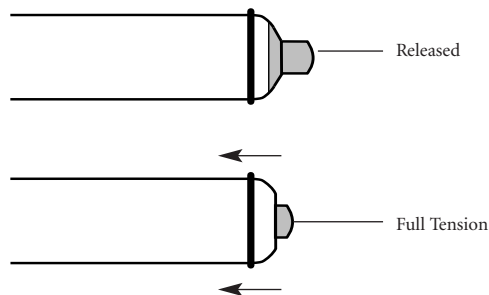
Turn biospring adjustment nut clockwise (D) until spring is under full tension (Figure 16).

To prepare for application of the frame, remove “O”-Rings, and place selected clamps on the tube. Once the clamps are in place, replace the “O”-Rings to prevent the clamps from sliding off the frame during the procedure (Figure 17).

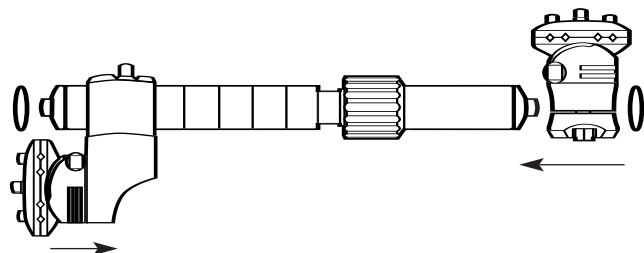
**Fig 15**



**Fig 16**



**Fig 17**

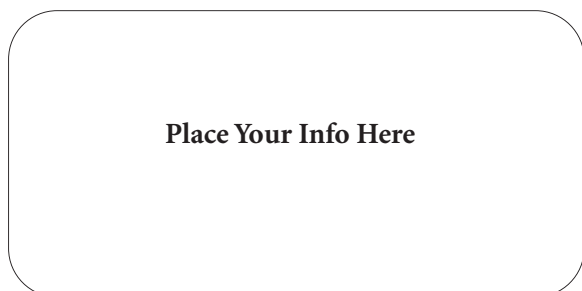


# References

1. Billings A, Scott DF, Camargo MP, Hofmann AA.: High Tibial Osteotomy with a Calibrated Osteotomy Guide, Rigid Internal Fixation, and Early Motion. *JBJS* 82-A, No. 1, Jan. 2000.
2. Calista F, Pegreff P.: High Tibial Osteotomy: Osteotomy in Minus or Hemicallostasis with Monoaxial External Fixator? *Chir Organi Mov* 81(2), April 1996.
3. Coventry MB.: Proximal Tibial Osteotomy: A Critical Long Term Study of Eighty Seven Cases. *JBJS* 75-A, No. 2, Feb. 1993.
4. Coventry MB.: Osteotomy of the Upper Portion of the Tibia for Degenerative Arthritis of the Knee. *CORR*. Number 248, Nov. 1989.
5. De Pablos J, Herranz PG, Barrios C.: Progressive Opening -Wedge Osteotomy for Severe Tibia Vara in Adults. *Orthopedics*, Vol 21, No 12, Dec. 1998.
6. Elting JJ, Hubbell, JC.: Unilateral Frame Distraction: Proximal Tibial Valgus Osteotomy for Medial Gonarthrosis. *Contemporary Orthopaedics*, 27, Nov. 1993.
7. Kramer AS, Raab DJ, Kelikian AS, Goldstein WM.: New Technique for High Tibial Osteotomy: Distraction Valgus Osteotomy with External Fixator. Scientific Exhibit, 64th Annual Meeting AAOS, San Francisco, Feb. 1997.
8. Mont MA, Alexander N, Krakow KA, Hungerford DS.: Total Knee Arthroplasty after failed High Tibial Osteotomy. *Orthop Clin North Am* Vol 25, No. 3, July 1994.
9. Nagel A, Insall JN, Scuderi GR.: Proximal Tibial Osteotomy: A Subjective Outcome Study. *JBJS* 78-A, No. 9, Sept. 1996.
10. Naudie D, Bourne RB, Rorabeck CH, Bourne TJ.: Survivorship of the High Tibial Valgus Osteotomy: A 10 to 22 Year Follow-up Study. *CORR* No 367, Oct. 1999.
11. Price CT.: Unilateral Fixators and Mechanical Axis Realignment. *Orthop Clin North Am*, Vol 25, No 3, July 1994.
12. Meding JB, Keating EM, Ritter MA, Faris PM: Total Knee Arthroplasty After High Tibial Osteotomy. *JBJS* 82-A, No. 9, Sept. 2000.
13. Barr SJ.: Opening Medial Wedge High Tibial Osteotomy: Hemicallostasis vs. Tricortical Iliac Crest Graft. Poster PF 450, AAOS 68th Annual Meeting, Feb. 2001.

# Patient Instructions

## After Opening Wedge Osteotomy of Tibia



**Patient Name:** \_\_\_\_\_

### Pin Care

This is very important to the success of the procedure. Please follow the guidelines below.

#### Weeks 0 - 3

Clean the pins twice a day with Q-tips, hydrogen peroxide and saline mix. The solution should be roughly 1/2 hydrogen peroxide and 1/2 saline. Use as many Q-tips as needed until the entire pin is clean of dried blood and debris.

I recommend showering once a day, letting the water run over the fixator. This will also help keep the pin sites clean, and make cleaning them with a Q-tip easier. After you are done, cut a cotton gauze dressing, slide it around the pin, and wrap it with an ace bandage.

#### Weeks 3 - 10

Please get a soft bristled toothbrush and scrub each pin site in the shower with soap until clean. Then dress with a cotton gauze pad and ace wrap.

### Weight Bearing Status

You may be weight bearing as tolerated with crutches initially. As you start to feel better later on in the treatment you may use a cane or nothing at all. Make sure you move your knee as much as possible to keep full range of motion. If you are having trouble with this let me know.

### Distraction

This is how you grow your own bone to change the alignment of your leg. You will need to turn the fixator a number of times during the day which I will figure out for you. This process can be painful and may require you to take more pain medicine. This only lasts for two weeks, so hang in there!

#### Turn the fixator

\_\_\_\_\_ 1/2 turns in the morning and  
\_\_\_\_\_ 1/2 turns in the evening for  
\_\_\_\_\_ days to arrive at a total  
distraction distance of  
\_\_\_\_\_ as measured off of the blue  
Monotube™ Triax™ distractor.

Try to develop a schedule that you can remember easily so you won't forget! You can follow your progress on the markers of the blue Monotube™ distractor. You will come back to see me in the office on \_\_\_\_/\_\_\_\_/\_\_\_\_ at \_\_\_\_:\_\_\_\_. At that time we will check an X-ray to see if the correction is enough.

### Infection

Redness around the pin sites is normal, and is usually about the size of a dime. If this gets larger, or yellow drainage starts, or if you develop a fever, it could mean you have an early infection. Please call me and I'll see you in the office.

---

**Joint Replacements**

---

**Trauma, Extremities & Deformities**

---

**Craniomaxillofacial**

---

**Spine**

---

**Biologics**

---

**Surgical Products**

---

**Neuro & ENT**

---

**Interventional Pain**

---

**Navigation**

---

**Endoscopy**

---

**Communications**

---

**Imaging**

---

**Patient Handling Equipment**

---

**EMS Equipment**

Stryker Trauma AG  
Bohnackerweg 1  
CH-2545 Selzach  
Switzerland

[www.osteosynthesis.stryker.com](http://www.osteosynthesis.stryker.com)

The information presented in this brochure is intended to demonstrate a Stryker product. Always refer to the package insert, product label and/or user instructions before using any Stryker product. Surgeons must always rely on their own clinical judgment when deciding which products and techniques to use with their patients. Products may not be available in all markets. Product availability is subject to the regulatory or medical practices that govern individual markets. Please contact your Stryker representative if you have questions about the availability of Stryker products in your area.

Stryker Corporation or its subsidiary owns the registered trademark: Stryker  
Stryker Corporation or its subsidiary owns, uses or has applied for the following trademarks: Monotube™ Triax™

Literature Number: 5075-2-504  
LOT A2806

Copyright © 2006 Stryker  
Printed in Switzerland

