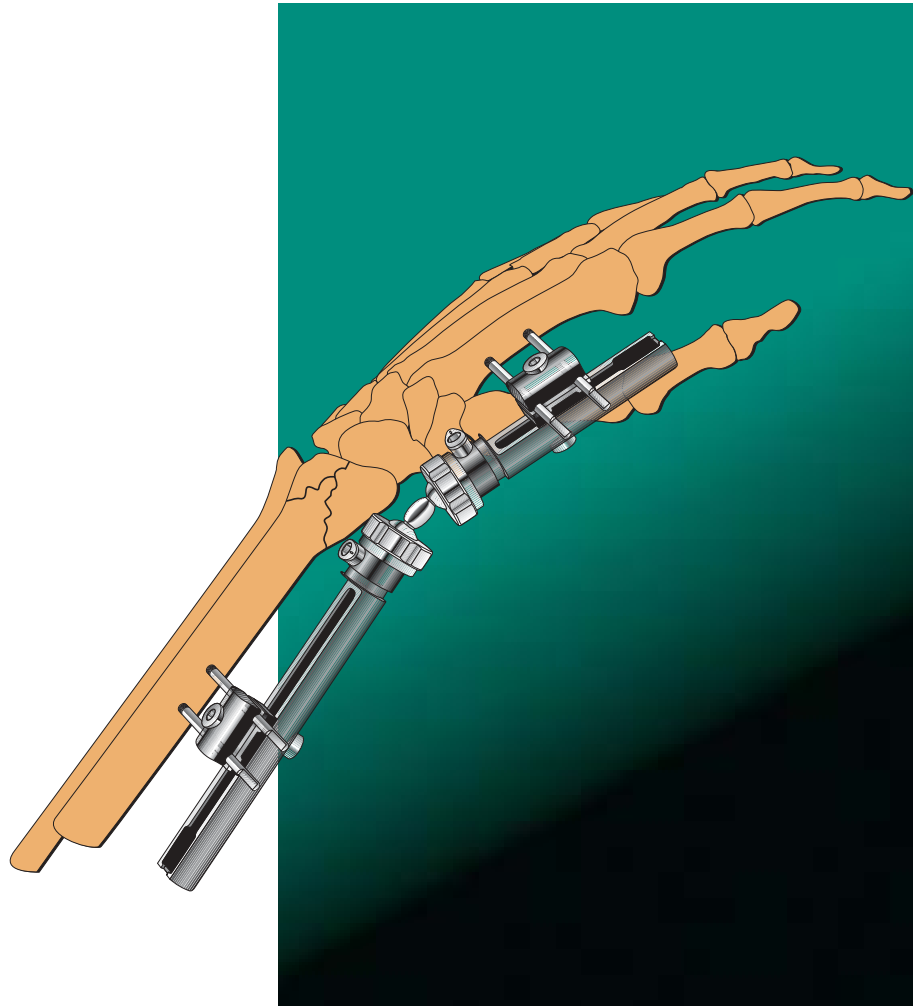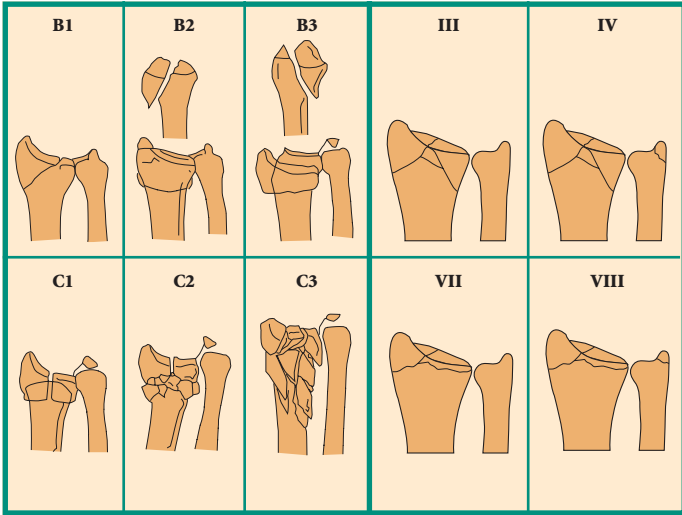


# The Pennig Dynamic Wrist Fixator

## Part A: Trans-Articular Application

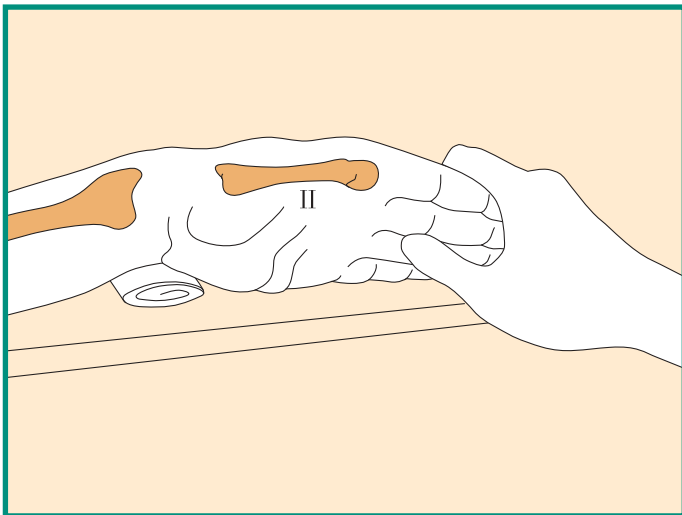
By Prof. Dr. D. Pennig





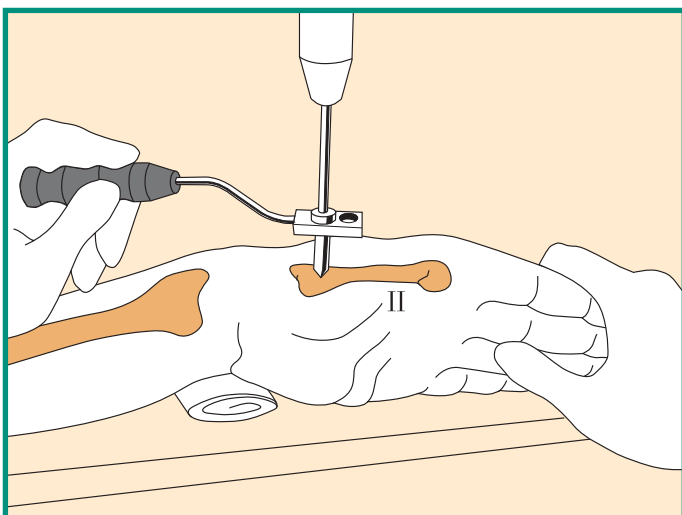
## TRANS-ARTICULAR APPLICATION

- The fractures that can be treated with this technique include AO type B and C fractures, and Frykman type III/IV and VII/VIII fractures, with very short peri-articular fragments or displaced intra-articular fractures.

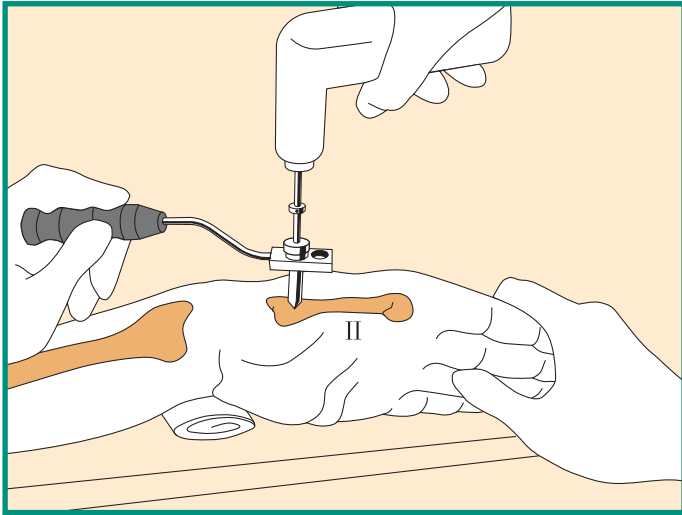


- Use a tourniquet. Place the wrist in moderate (manual) traction, flexion and radial abduction over a folded towel for support.

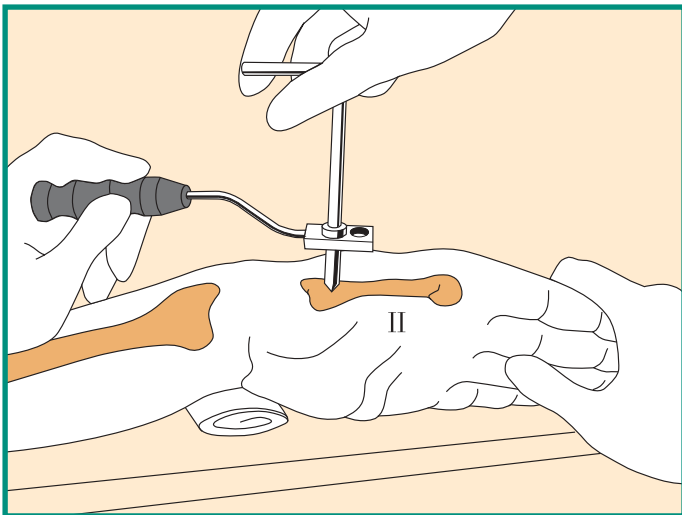
*Note: Forearm should be in neutral position.*



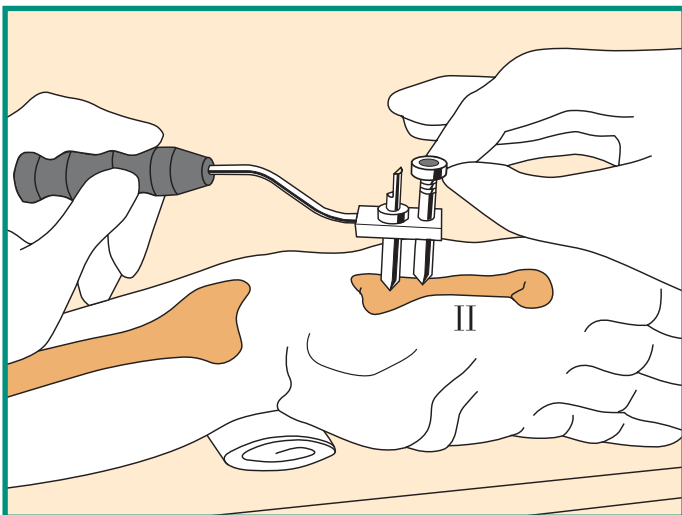
- Make a stab incision in the **FRONTAL** plane over the flare of the tubercle of the second metacarpal. Separate soft tissues down to bone and locate center of bone with a trocar inserted into the short screw guide in the template with handle.



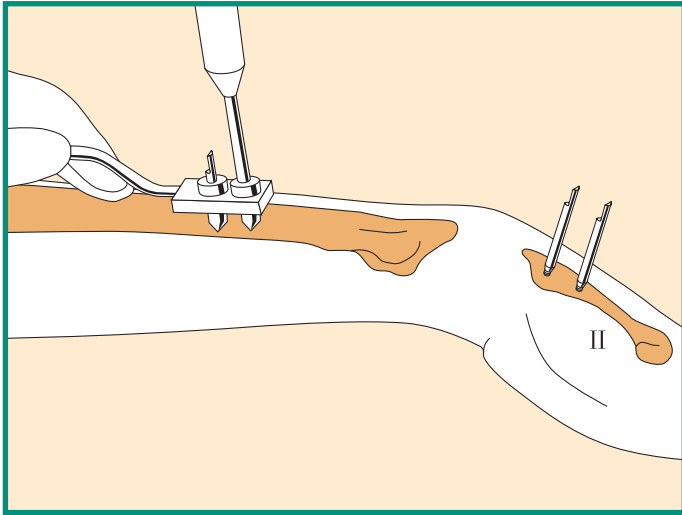
- Remove the trocar and insert a drill guide into the screw guide. Drill both cortices with a 2.7 mm drill bit with stop collar.



- Remove the drill guide and insert the first screw (70/20 mm) into the second metacarpal in the frontal plane to a depth of about 10 mm.



- Insert LONGER screw guide into the template and repeat the above procedure for distal metacarpal screw (70/20 mm).

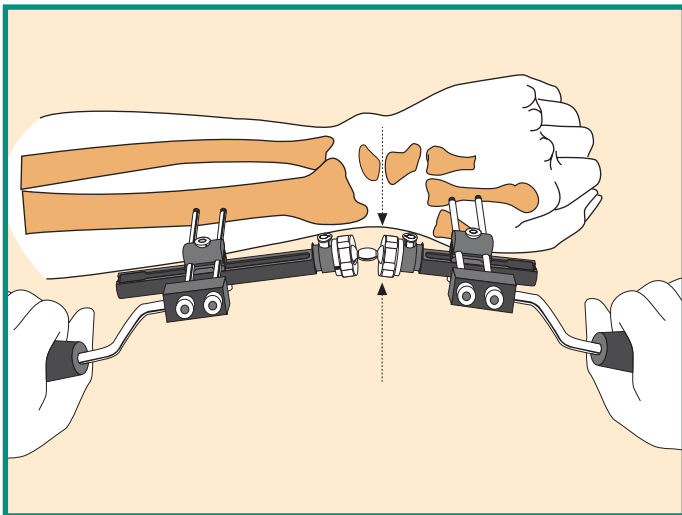


- Insert the radial screws in the frontal plane through a **single 25 mm incision**, after blunt dissection down to the bone, to avoid injury to the superficial branch of the radial nerve.

The distal radial screw should not be closer than 4 cm from the fracture site. Use a 2.7 mm drill bit and 70/20 mm screws.

When all four screws are inserted, check that they just penetrate the second cortex.

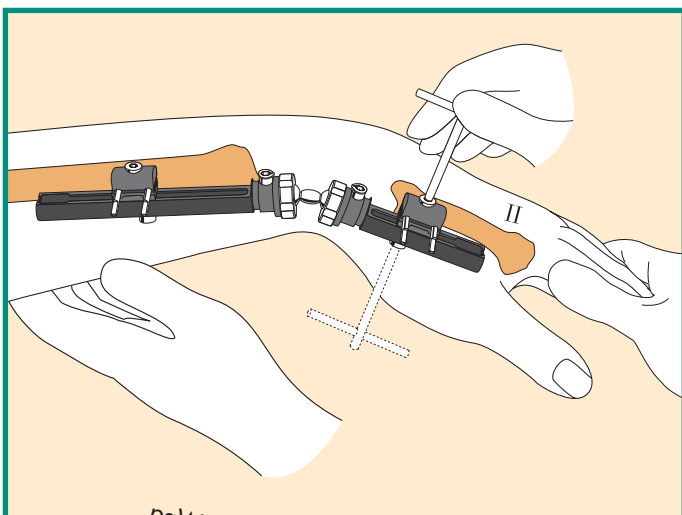
*Note: Tapered screws cannot be backed out.*



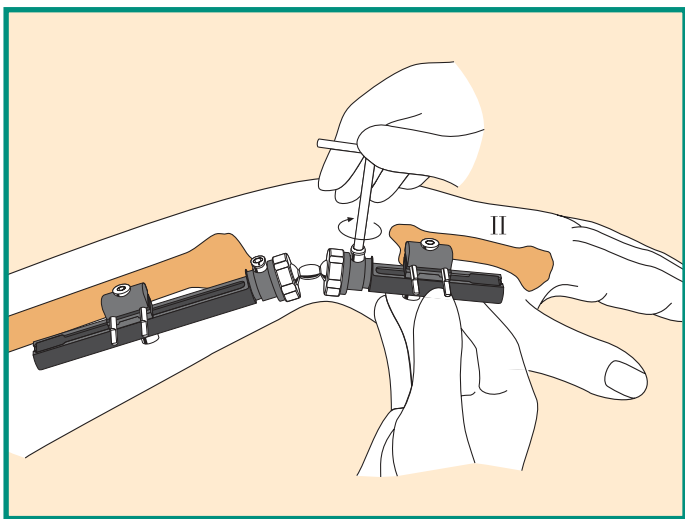
- Before fixator application, ensure that the collars are fully tightened. Apply the fixator to the bone screws with cams, clamp cover screws and clamp anchoring screws loosened. Set fixator 15-20 mm from the skin surface, and tighten the clamp cover screws. Use templates with handle, with screw guides in place, to reduce fracture under image intensification.

Gentle manipulation should be used, with manual traction only when necessary. Lock the double ball-joint, ensuring that the distal ball-joint is in line with the Capitate-Lunate joint line.

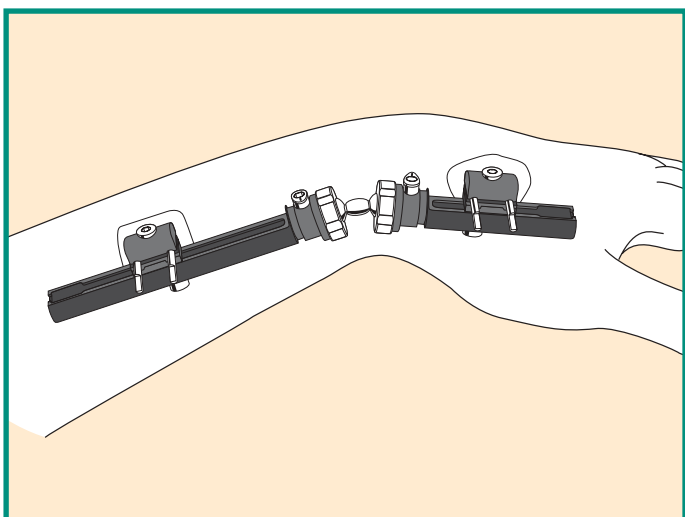
If radial length has not been restored, if there is a persistent radial angulation or if displaced articular fragments are present, supplementary techniques may be needed at this stage.



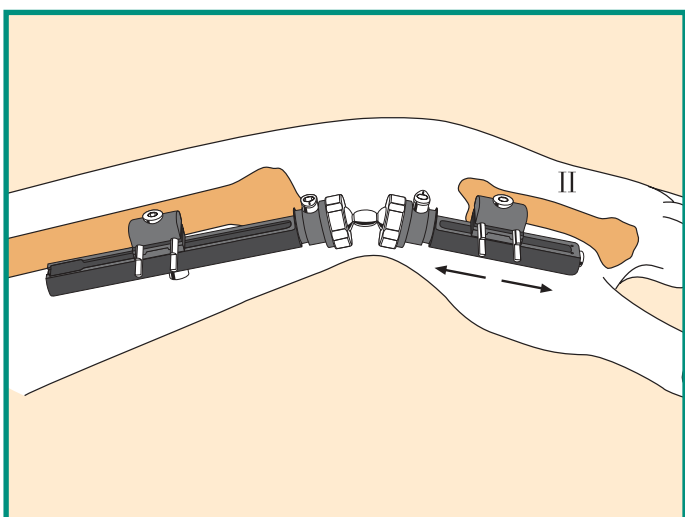
- When reduction has been achieved, finally tighten all clamp cover and clamp anchoring screws.



- Complete locking of the double ball-joint by turning the cams clockwise until very tight (dot moves between 90 and 170 degrees).  
In case of radio-ulnar instability or injury to the ulnar disc, use the Ulnar Outrigger Clamp, (see page 7 below).



- At the conclusion of the operation, move the patient's fingers to check for any skin or soft tissue tethering around the screws (which, if present, may require additional skin/soft tissue release). Apply dressing around screws.



- In cases where treatment has been delayed, the compression-distraction module may be used, and the wrist joint temporarily distracted in a gentle manner to allow joint reconstruction and/or bone grafting. **The over-distraction must be released at the end of surgery.**

## SUPPLEMENTARY TECHNIQUES

### Bone Grafting

- Defect visible on AP view after fracture reduction

Incision over the radial styloid; fill with small bone block. It is sometimes necessary to elevate the radial fragment with a bone elevator to restore radial length. (Caution: superficial branch of radial nerve).

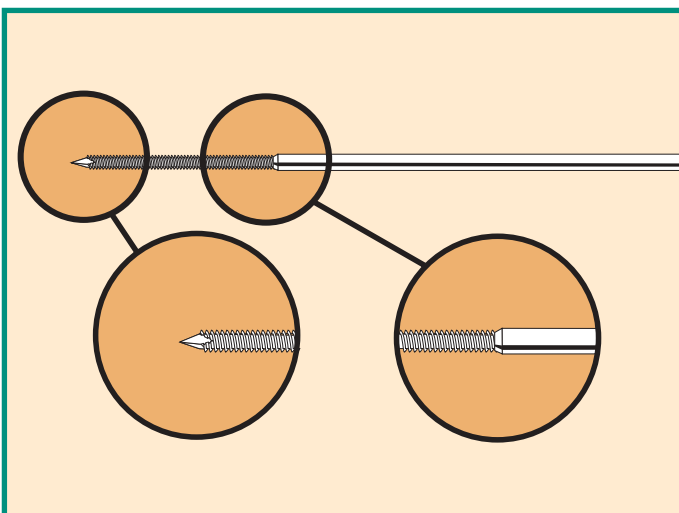
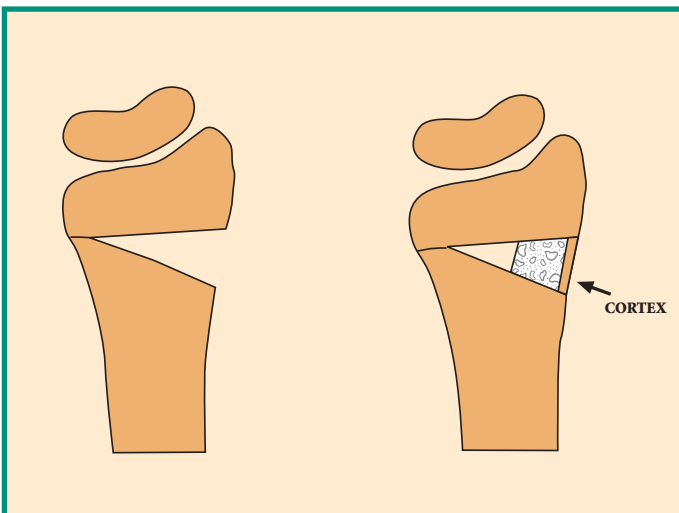
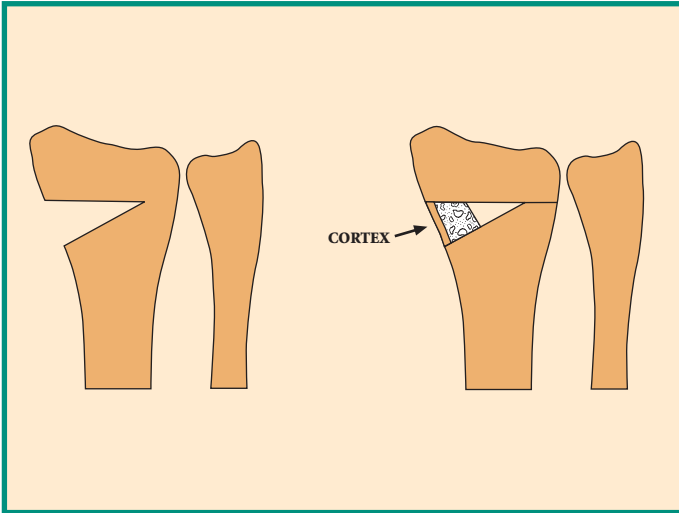
*Note: Use the iliac crest as a donor site and remove small blocks with one cortex.*

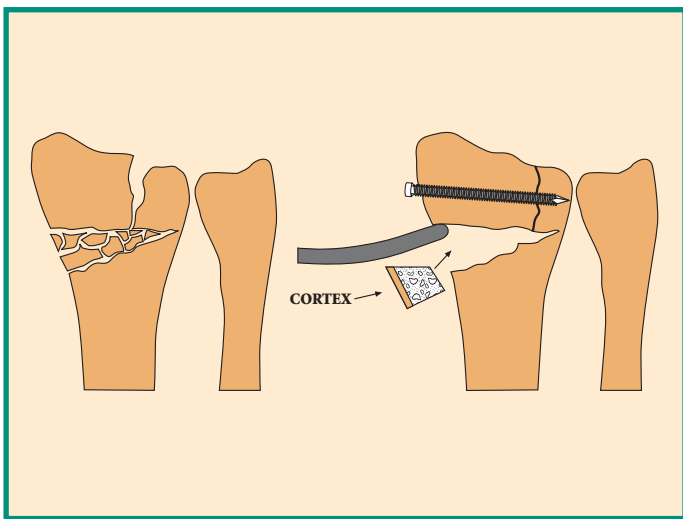
- Defect visible on lateral view after fracture reduction

Incision over the dorsal aspect of the distal radius; fill with small bone block. It may be necessary to elevate radial fragment to restore dorsal angle. (Caution: extensor pollicis longus tendon).

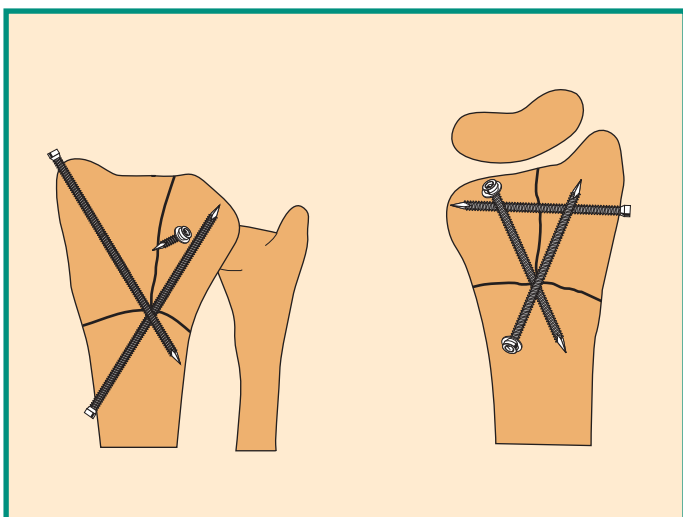
### Limited Internal Fixation

- Use the Orthofix Fragment Fixation System which is specially designed for this.

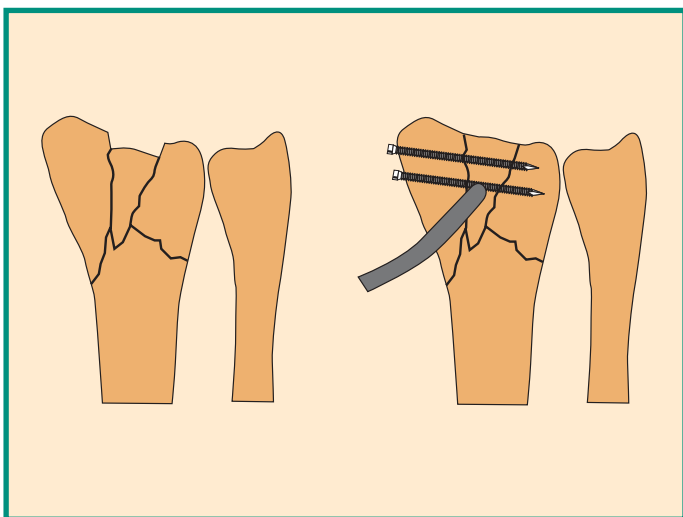




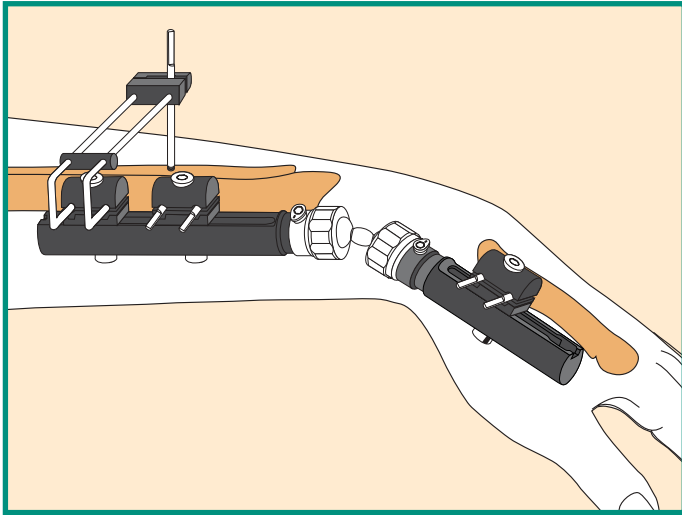
- Restore articular surfaces using a bone elevator if necessary, using Orthofix Fragment Fixation wires to maintain reduction and a small bone graft to fill any defect.



- This type of fracture may be satisfactorily reduced by ligamentotaxis. If redisplacement occurs, use the Orthofix Fragment Fixation System to maintain reduction as shown.



- Where a depressed fragment remains unreduced on ligamentotaxis, elevate with a bone elevator and secure using the Orthofix Fragment Fixation System.



### Use of the Ulnar Outrigger

- Mount it on a second screw clamp on the radial module. Following ulnar reduction and temporary stabilization of the distal radio-ulnar joint with a K-wire, a single screw is inserted into the ulna from a dorsal position. (Caution: avoid injury to ulnar artery or nerve). Pronation and supination are now blocked.

The outrigger is usually removed at 3-4 weeks.

The Orthofix Quality System has been certified to be in compliance with the requirements of:

- Medical Devices Directive 93/42/EEC, Annex II - (Full Quality System)
- International Standards EN 46001/ISO 9001

for orthopaedic external fixator systems including bone screws, nails and wires, sterile external and internal fixation systems.



See “Orthofix External Fixation System” instruction leaflet (PQ EXF) and appropriate Operative Manual prior to use.

Your Distributor is:

[www.orthofix.com](http://www.orthofix.com)



**ORTHOFIX** - Wonersh House - The Guildway - Old Portsmouth Road  
Guildford - Surrey GU3 1LR - England  
Tel. 44 1483 468800 Fax 44 1483 468829