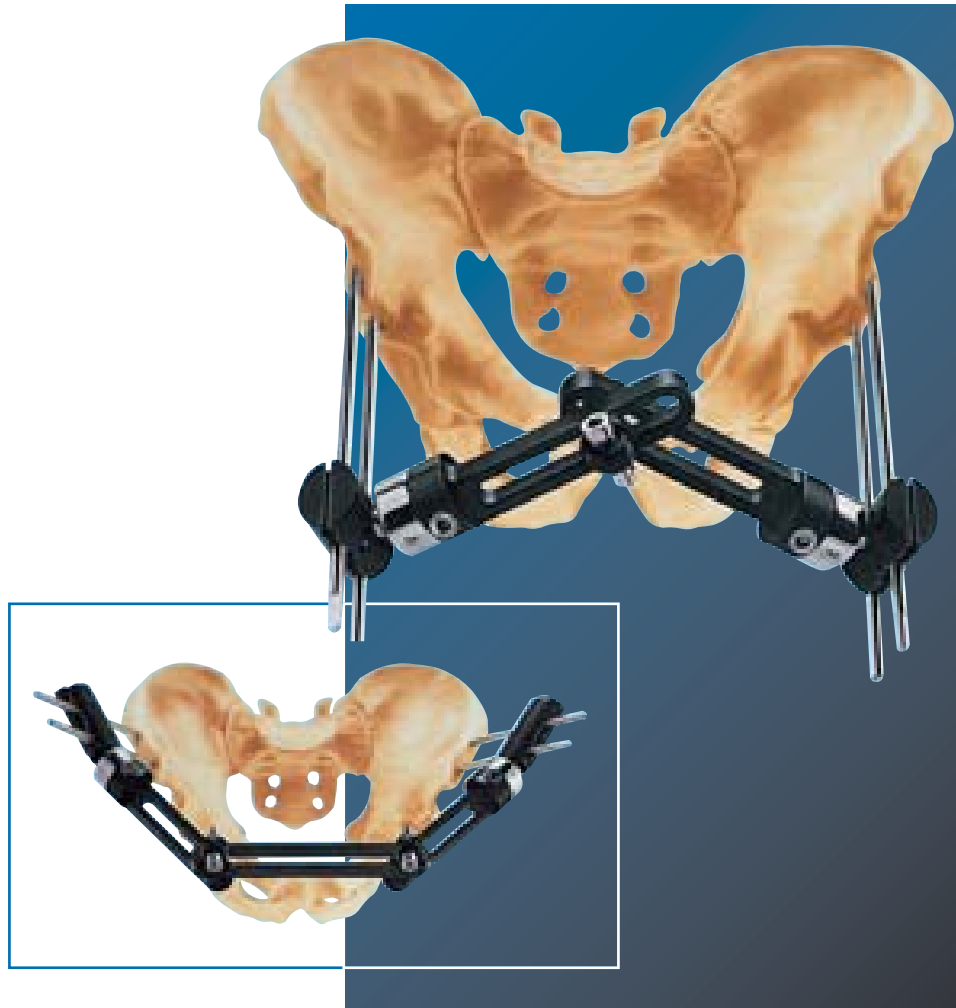

Pelvic Applications

Fractures and Disruptions of the Pelvic Ring

By Prof. Dr. D. Pennig and Dr. L. Renzi-Brivio

INTRODUCTION	1
CLASSIFICATION OF PELVIC RING INSTABILITIES	2
Summary of Management Strategy	3
EQUIPMENT REQUIRED	4
Fixator Assembly	5
Maintenance and Sterilization	5
PRE-OPERATIVE TECHNIQUE	6
OPERATIVE TECHNIQUE	
A. Anterior Application	7
B. Iliac Crest Application	10
- Application with Straight Clamps	10
- Application with Ball-Jointed Modules for Independent Screw Placement	11
POST-OPERATIVE MANAGEMENT	12
THE MANAGEMENT OF POSTERIOR PELVIC DISRUPTIONS AND FRACTURES	14
BIBLIOGRAPHY	15

Injuries to the pelvic ring are usually seen in multiple trauma victims. The major threat from pelvic ring injuries is the blood loss, the source being arterial bleeding, venous bleeding and bleeding from cancellous bone. The blood loss in such a situation can be anything from half a liter to several liters. As a general rule, an unstable pelvic ring is best stabilized as soon as possible, and preferably within 6 hours of injury. In the treatment protocol it has the highest priority of all skeletal injuries (Rieger et al, 1991). Open injuries increase considerably the likelihood of a fatal outcome, and a rectal as well as vaginal examination are part of the routine assessment to identify any hidden tears in these areas. As described by Slätis and Huittinen (1972), the benefit of external fixation is that it is minimally invasive and can be applied rapidly. Stabilization of the pelvic ring is provided and the patient can then be moved and turned for further diagnostic measures if indicated. Fixation of the pelvic ring reduces the likelihood of further blood loss and allows the tamponade effect to occur (Müller-Färber and Müller, 1984).

The possibility of persistent bleeding must be considered, however, and carefully monitored after application of the fixator. Later on, the patient may receive physiotherapy and be mobilized.

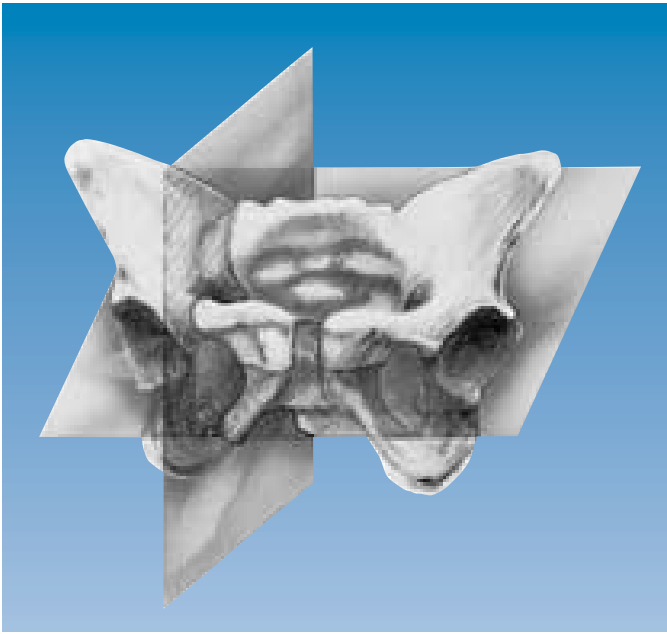In comparison with anterior internal fixation techniques, the benefit of rapid application outweighs the minimal inconvenience. As described in this manual, external fixation is intended as a definitive treatment and not as a temporary measure.

Mechanical studies on fresh-frozen cadaver pelvis with experimentally created double-vertical Malgaigne (1859) fracture/dislocations have shown that the Classic Orthofix Dynamic Axial Fixator (DAF) is comparable to the Pittsburgh triangular frame in terms of rigidity and fracture stabilization, but that the former is 4-7 times stiffer at lower load levels (Bell et al., 1988). The Orthofix frame has an application time half that of the Pittsburgh frame and the ability to generate greater compression at the fracture/dislocation site, which may decrease cancellous hemorrhage.

Stabilization with the Orthofix Pelvic Fixator is achieved by means of self-drilling screws inserted into the pelvis, and a fixator assembly which consists of two primary links joined by a connector unit. A supplementary link may be used in obese patients or in iliac crest applications. With this new design, the ball-joint capacity has been increased to facilitate fracture reduction, and handling of the fixator has been improved by the simplicity of the system. Furthermore, the sliding link system allows the fixator to cover a wide range of pelvic sizes, thus significantly reducing the inventory.

As an alternative to the Pelvic Fixator, stabilization can be achieved using the Orthofix ProCallus body (usually standard or long model).

With three-dimensional frames (Slätis or Pittsburgh) the iliac crest is the prime target for insertion of the screws. This has certain disadvantages, because reduction of the pelvic displacement from the top of the pelvis is much more difficult than from the front. In accordance with the biomechanical studies of Pauwels (1965), who described the symphysis pubis and the pubic rami as a tension band for stabilizing the pelvic ring, an anterior approach for pin insertion was proposed (Pennig et al., 1989).



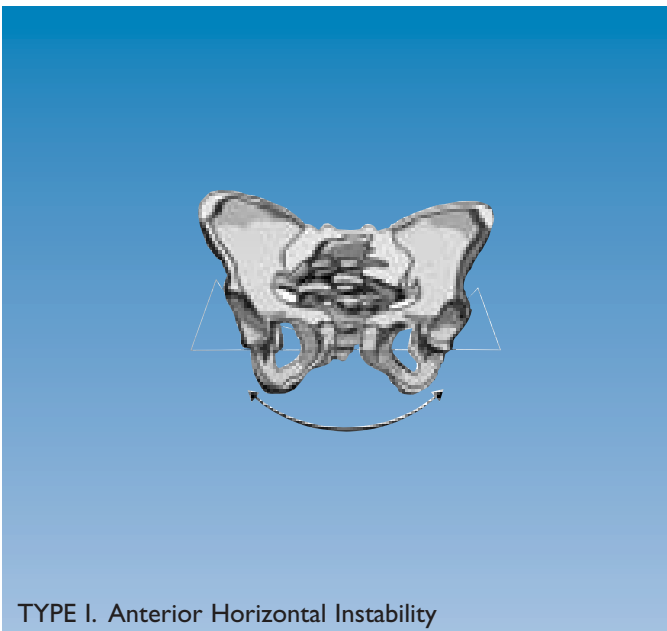
A retrospective analysis (Haeske-Seeberg, 1988) of 332 pelvic injuries in 755 multiple trauma victims was used to study the pattern of pelvic ring injuries and to develop a classification system (Pennig).

There are two main planes of instability: a horizontal plane and a vertical plane.

Pelvic ring instabilities are divided into three types.

Type I is defined as an **anterior horizontal instability** with a lesion of the anterior pelvic ring (symphysis pubis or pubic rami) and a stretching or rupture of the anterior portion of the sacroiliac ligaments without displacement of the posterior elements of the pelvic ring (SI joint, ilium or sacrum).

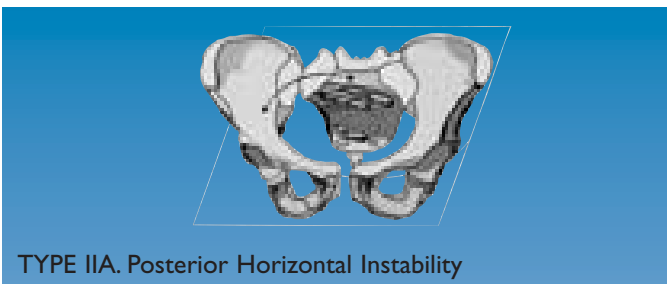
Type I Instability requires Anterior External Fixation



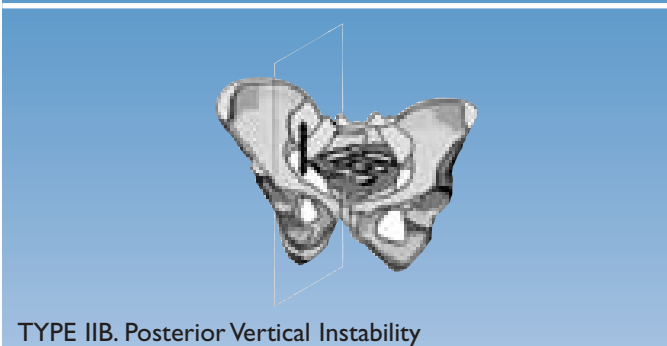
TYPE I. Anterior Horizontal Instability

Type II is defined as a **posterior instability**, IIA being a posterior horizontal instability, IIB a posterior vertical instability. The lesion of the posterior ring consists of a fracture and/or disruption of the SI joint, ilium and/or sacrum. The anterior pelvic ring in these cases has to show no injury, or a non-significant injury without displacement.

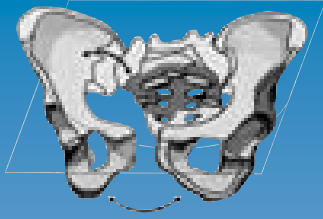
Type II Instabilities require Posterior Internal Fixation



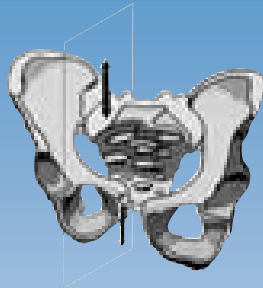
TYPE IIA. Posterior Horizontal Instability



TYPE IIB. Posterior Vertical Instability



TYPE IIIA. Antero-Posterior Horizontal Instability



TYPE IIIB. Antero-Posterior Vertical Instability

Type III is an **antero-posterior instability**, IIIA being an antero-posterior horizontal instability, IIIB an antero-posterior vertical instability. The anterior pelvic ring in these cases shows a lesion with displacement of the symphysis pubis and/or the pubic rami. The posterior elements comprise a fracture and/or disruption of the SI joint, ilium and/or sacrum.

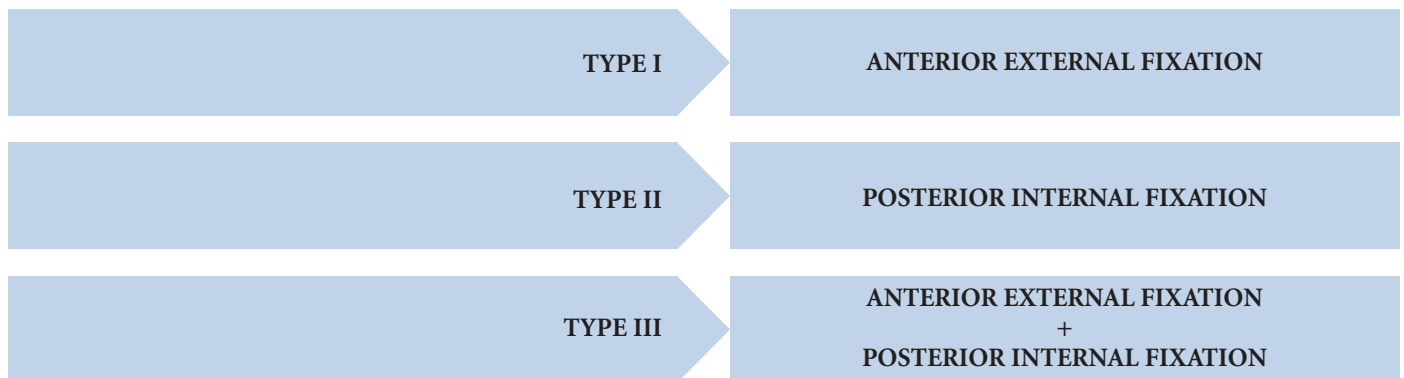
Type III Instabilities require:

Stage 1. Anterior External Fixation

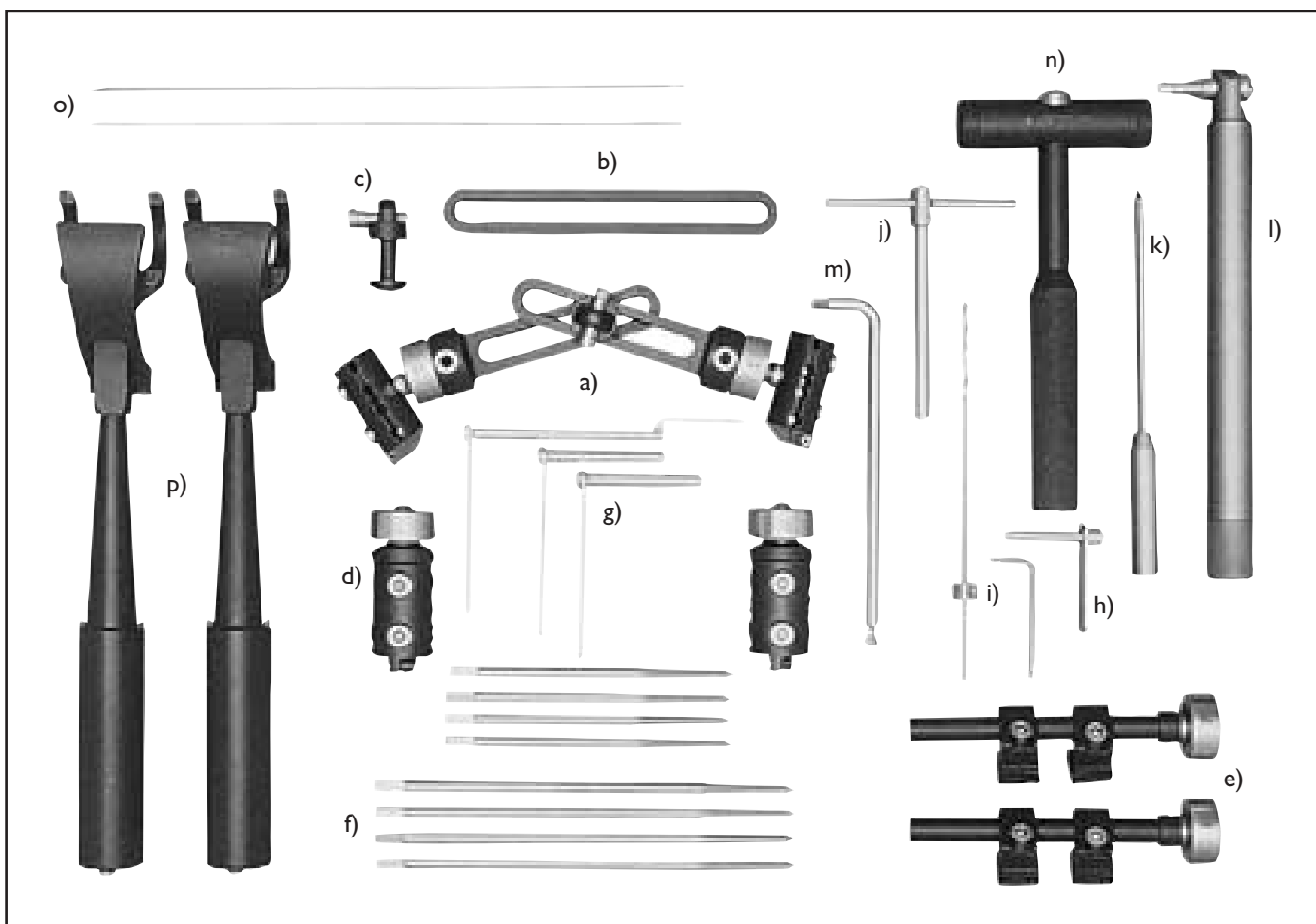
Stage 2. Posterior Internal Fixation

The classification is applied to each hemipelvis, with the POSTERIOR injury component being used to define the side of the injury.

SUMMARY OF MANAGEMENT STRATEGY



EQUIPMENT REQUIRED



a) One Pelvic Fixator for anterior application, complete with: two Primary Links (10087), one Connector Unit (10089), two Cams (10004), two Bushes (90005), two T-clamps (90007).

b) One Supplementary Link (10088), used when treating obese patients, or in patients who may need abdominal surgery and the iliac crest application has been used.

c) An additional Connector Unit (10089), for use in association with a Supplementary Link.

d) Two Straight Clamps (90006) for use in the iliac crest application.

e) Two Ball-Jointed Modules for Independent Screw Placement (10054) where the iliac crest application is used.

f) Four self-drilling screws with 6/5 mm thread diameter. Where the patient is of average size 150/50 screws are recommended. In patients who are obese, or where the iliac crest application is employed, 220/50 screws should be used.

g) Two screw guides (11102 or 11103) or two special pelvic screw guides (11141)

h) One drill guide 3.2 mm diameter (11106 or 11116)

i) One drill bit kit (drill bit 3.2 mm diameter, stop unit and 3 mm Allen Wrench) (13003)

j) T-Wrench (11000)

k) Tapered Trocar (11004)

l) Torque Wrench (10025)

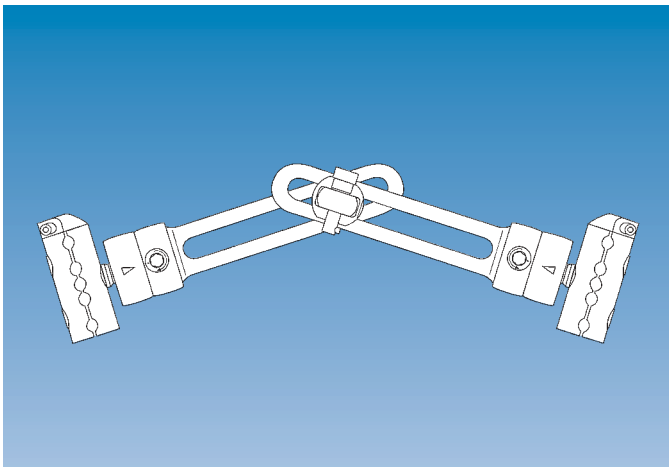
m) 6 mm Polyhedral Allen Wrench (10017)

n) Hammer (11111)

o) Two Kirschner wires, 1.6 mm diameter

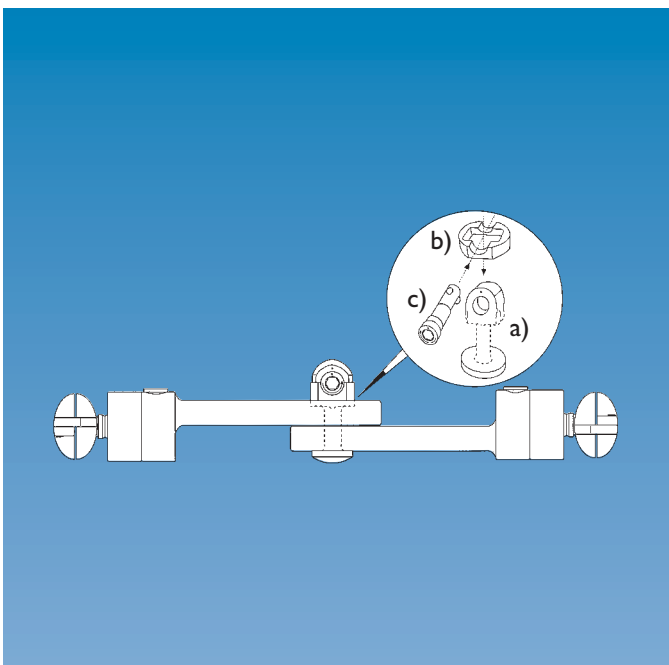
p) Reduction Forceps (11201)

EQUIPMENT REQUIRED



FIXATOR ASSEMBLY

The fixator consists of two primary links with ball-joint attachment.



The primary links are joined via a connector unit which comprises:

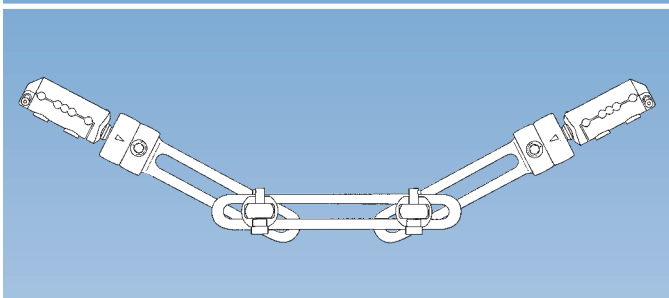
- a) a connector post
- b) a grooved bush
- c) a self-retaining cam

To ensure that the clamps for the bone screws are correctly aligned when the fixator is assembled, the links must be presented to one another as shown above, one with the step beneath the collar facing upwards, and one with the step facing downwards.

When assembling the fixator, insert the connector post into the two primary links and apply the grooved bush over it. Insert the self-retaining cam, with its pin facing downwards, from the side of the larger groove.

If the pin at the extremity of the cam is not facing downwards, insertion of the cam is not possible.

Slight rotational movements of the self-retaining cam may be needed to introduce it fully.



When a supplementary link is used the two primary links are attached to the same side of the supplementary link with the step beneath the collar of each primary link facing the same direction.

MAINTENANCE AND STERILIZATION

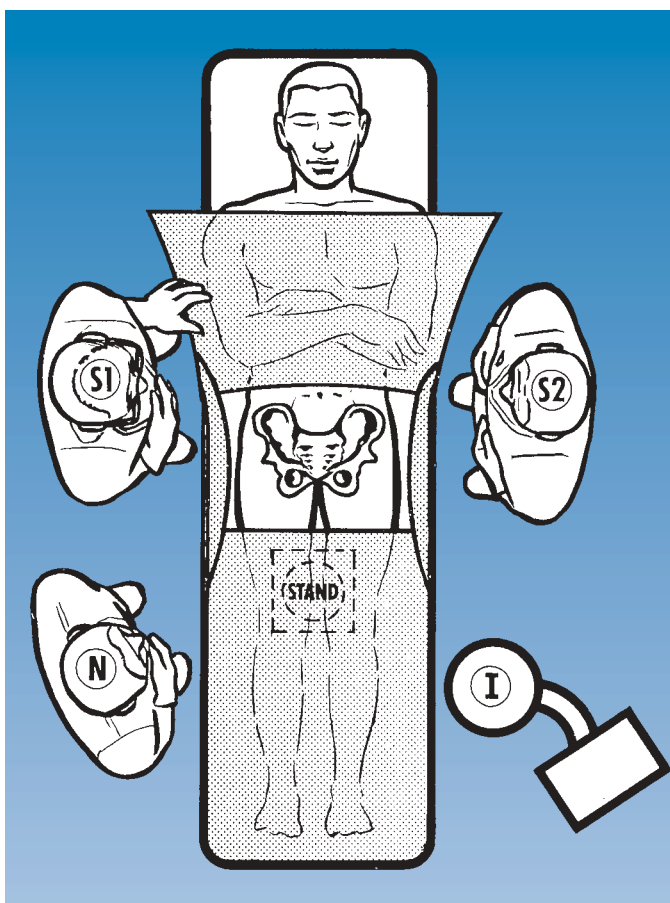
When products are used for the first time, they should be removed from their containers and properly cleaned using medical grade alcohol 70% + distilled water 30%. After cleaning, the devices should be rinsed with sterile distilled water and dried using clean non-woven fabric.

Prior to surgical use, the fixator, as well as the bone screws and instrumentation should be cleaned as described above and sterilized by steam autoclaving following a validated sterilization procedure, utilizing a prevacuum cycle (Orthofix recommends the following cycle: steam autoclave 132°-135°C [270°-275°F], minimum holding time 10 minutes).

Following each use, the fixator should be completely dismantled for cleaning, but it may be sterilized in the assembled state provided the locking screws, cams and self-retaining cam are left loosened.

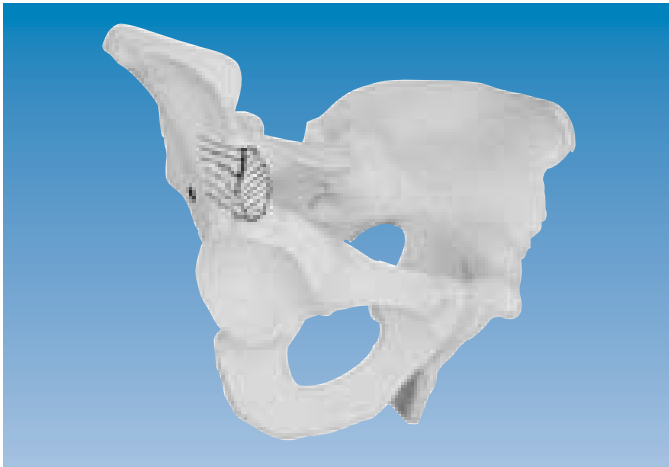After every use, it is recommended that the cams and bushes are changed and on no account should they be re-used if the dot on the cam can be rotated in excess of 170°. The connector unit must also be changed if on tightening the self-retaining cam the dot on the surface of the cam moves more than 170° from the white dot on the surface of the connector post.

The remaining fixator components should be carefully examined for possible damage. Note that bone screws are for single use only and must **not** be re-used.



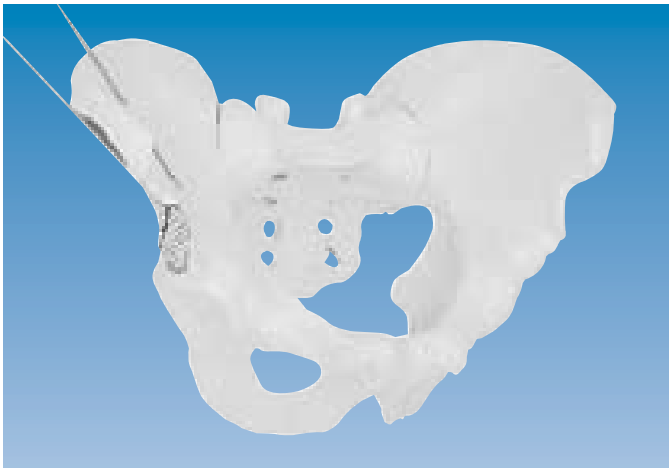In positioning the patient, ready access of the Image Intensifier to allow AP imaging of the pelvis must be ensured pre-operatively, and the patient is moved on the operating table if necessary. The patient should be in the supine position and lower abdomen and proximal femora are shaved and disinfected. Draping is then carried out, leaving free access from the umbilicus to the pubic area.

The Image Intensifier (I) is positioned opposite the surgeon (S1), who should begin with the uninjured side. One assistant (S2) is required and the scrub nurse (N) should work from the same side as the surgeon. The legs of the patient should be accessible to allow an unscrubbed assistant to help with the reduction.

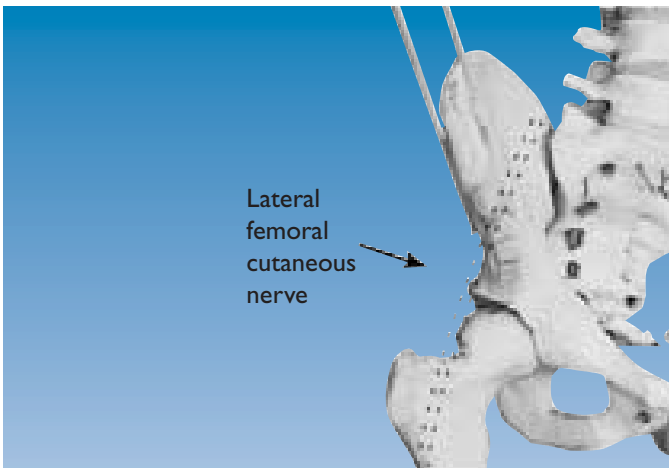


A. ANTERIOR APPLICATION

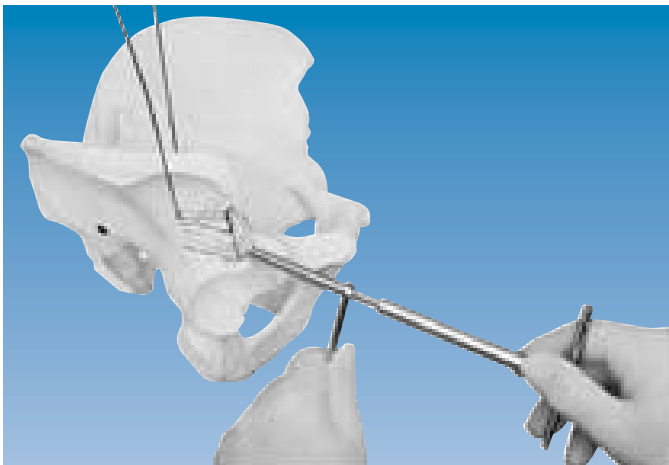
It is always advisable, where possible, to commence with the uninjured side, especially on the first few occasions that the external fixator is applied. The landmark for screw insertion is the anterior superior iliac spine which can be easily palpated. The screws should be inserted between the inferior and the superior iliac spines, starting with the screw at the level of the anterior inferior iliac spine. Screws should be angled slightly upwards to avoid penetration of the acetabulum and to allow the fixator body to be positioned in line with the anterior pelvic ring.



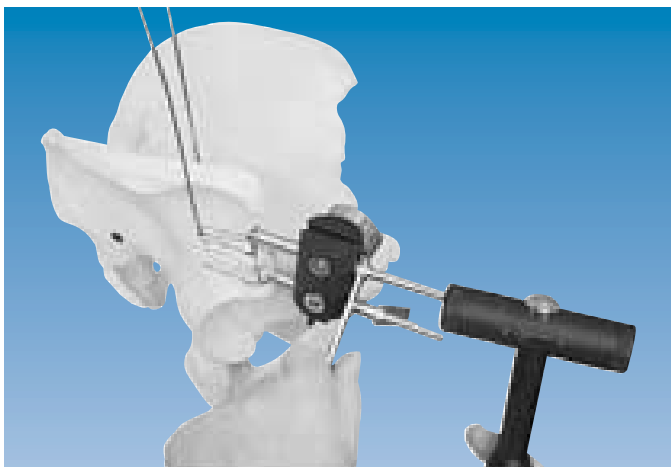To establish the orientation of the hemipelvis, which may be significantly rotated externally (most likely) or internally, a pair of Kirschner wires (1.6mm) should be used. The first Kirschner wire is inserted from the iliac crest along the inner table of the ilium, while the second Kirschner wire is inserted along the outer table of the ilium.



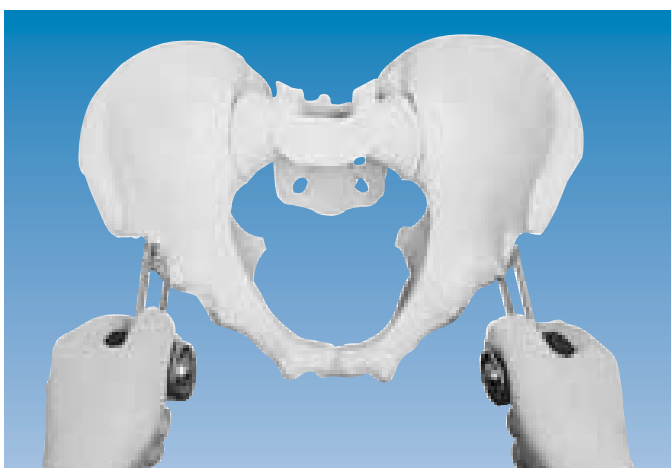
Once the position of the hemipelvis has been established, a short, 3 cm incision should be made, starting just below the anterior superior iliac spine. The lateral femoral cutaneous nerve must be protected from injury, by means of Langenbeck retractors. The bone should be exposed, and the screw guide for the first bone screw inserted down to the bone, taking account of the orientation provided by the two Kirschner wires.




A self-drilling, self-tapping screw with its long axis in the SAGITTAL PLANE, should be hammered through the cortex with gentle taps and then screwed home with the T-wrench. It is of the utmost importance not to force the screw in any direction, but rather to let it find its way between the inner and outer tables of the ilium. The depth of insertion is 40-50 mm, which is almost the entire thread length.



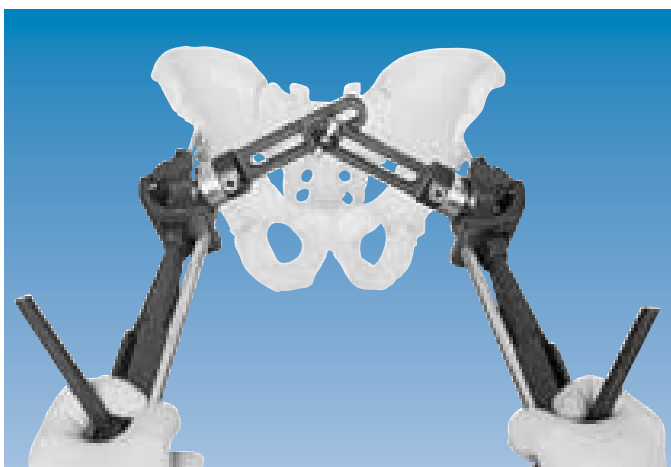The first screw, in its screw guide, is now housed in the first seat of the T-clamp. The second screw should be placed about 2 cm proximal to the first screw, which will correspond to the third or fourth clamp seat above it. It is important to make sure that the screw is not forced outside the pelvis. After a certain amount of practice, it may be preferable to insert the screws parallel to one another in both planes, free-hand. In young patients (16 years and under), the use of a drill bit (3.2 mm) to penetrate the hard cortex to a depth of 1 cm, may be necessary. If a drill bit is used, this power instrument should be handled with extreme care, and a drill guide must be employed to protect the soft tissues.



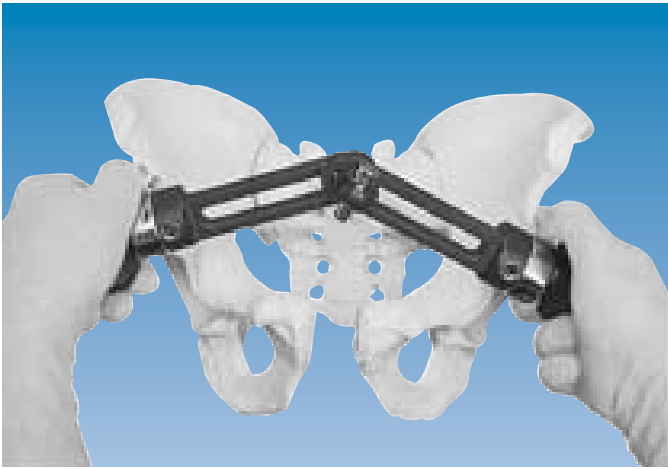When both screws have been inserted into the first hemipelvis, the procedure is repeated for the opposite hemipelvis. When choosing screw direction in the injured hemipelvis, its rotation must be taken into account. Once the second pair of screws has been inserted, both pairs should be grasped firmly to ensure that they will be able to withstand the loads exerted upon them by the fixator during the process of reduction. Should there be any doubt about the appropriateness of screw placement, an X-ray may be taken at this stage.



T-clamps should be mounted on each pair of screws at a similar distance from the skin. The fixator is now applied and reduction carried out. To ensure that the clamps for the bone screws are correctly aligned when the fixator is applied, the links must be presented to one another as shown, with the steps beneath the collars pointing in opposite directions.

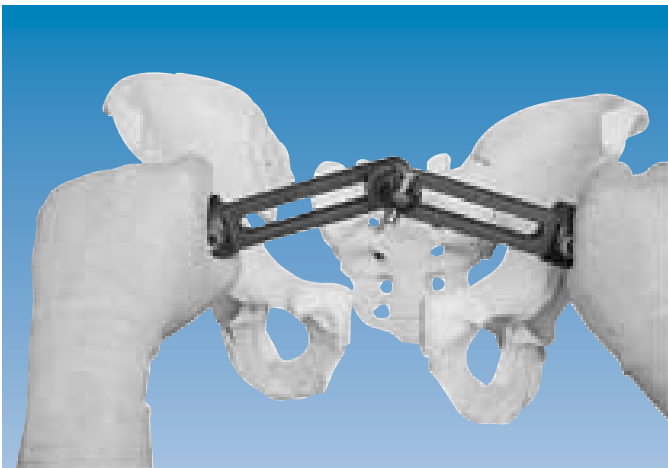


To assist reduction, which in most cases implies internal rotation of the injured side, the legs may be used to gain leverage. Reduction can be accomplished with the manipulation forceps, which distance the surgeon's hands from the X-ray beam.

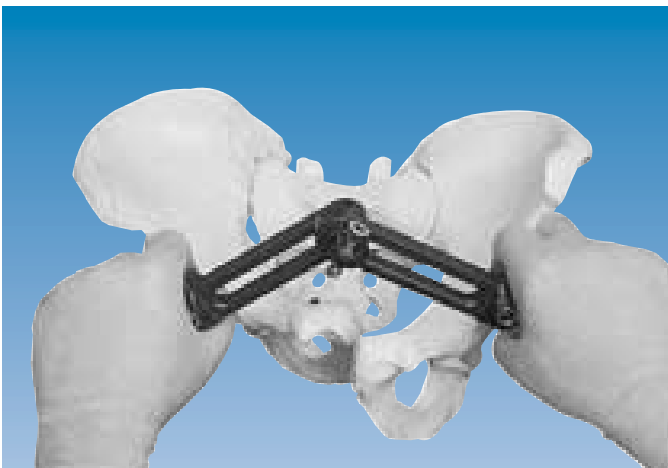

With the ball-joints and connector unit cam unlocked, reduction of the following types of pelvic displacement can be achieved under image intensification.

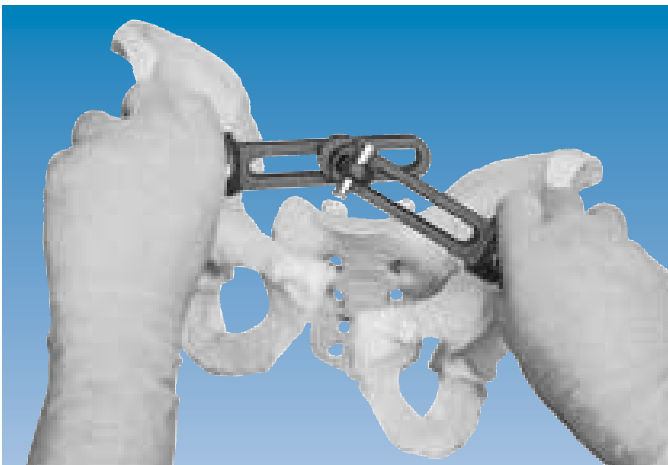
Type I injury [open book] (see also page 2).



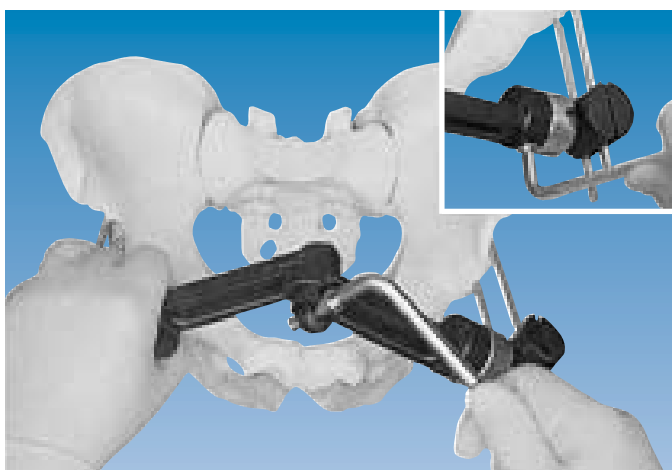
Type IIIA injury with external rotation of the hemipelvis [antero-posterior horizontal instability] (see also page 3).



Type IIIA injury with internal rotation of the hemipelvis [antero-posterior horizontal instability].

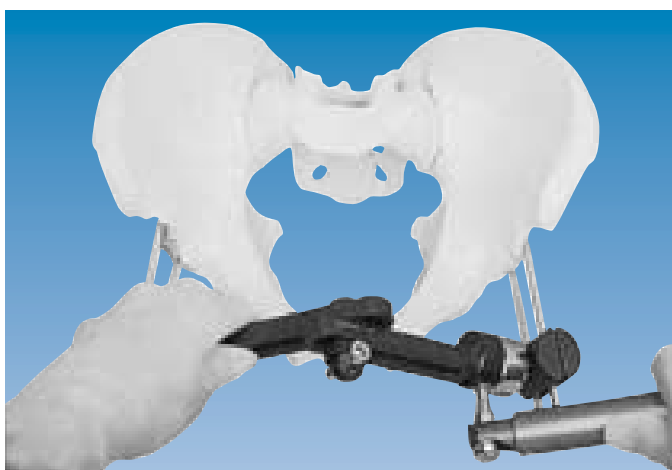


Type IIIB injury [antero-posterior vertical instability] (see also page 3).



The nature of the fixator with its ball-joints and sliding links is such that it was possible to simulate all of the above examples of pelvic displacement starting from the neutral position shown opposite.

After reduction has been achieved, the connector unit cam and the ball-joints are tightened with the Allen wrench.

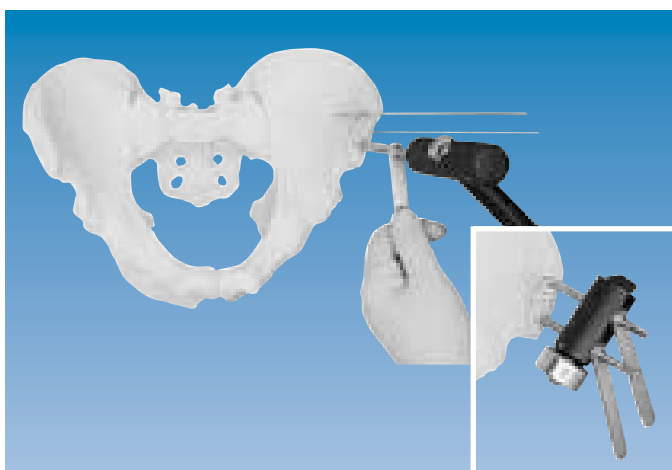


It is important to make sure that the minimal distance between the fixator and the skin in all circumstances is more than 5 cm, to allow for the bowel distention which commonly occurs during intensive care management of these patients. Should it be necessary, the fixator can be adjusted to take account of abdominal distention by loosening the clamp screws and moving it away from the pelvis, following which, the clamp screws are re-tightened.

Final locking of the ball-joints is performed with the torque wrench.

B. ILIAC CREST APPLICATION


If it is desired to use this approach, there are certain technical aspects to be considered. Whereas the iliac crest itself has a diameter of 10-15 mm, immediately below the iliac crest the diameter of the bone is often less than 5 mm (distance between the two cortices). The likelihood of penetrating either the inner or the outer table is therefore considerable. In addition to the above, mention has already been made of the fact that reduction of pelvic displacement from the top rather than the front, is more cumbersome (compare closing a book from the top, or the front).



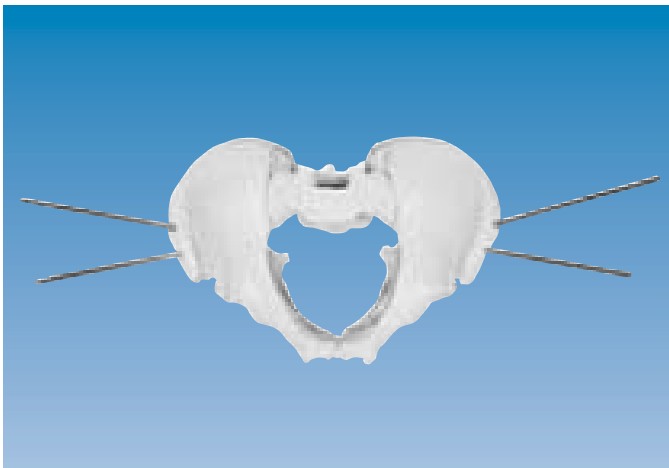
Application with Straight Clamps

Screws (220/50) should be inserted at an angle of 45° to the long axis of the body through a 3-4 cm incision over the iliac crest. The first screw is inserted 1.5-2.0 cm posterior to the anterior superior iliac spine through a screw guide.

The straight clamp is then mounted on the screw guide, and the second screw inserted about 2 cm posterior to the first. Because of the hardness of the iliac crest, especially in younger patients, the path for the screws should be predrilled using a 3.2 mm drill bit.



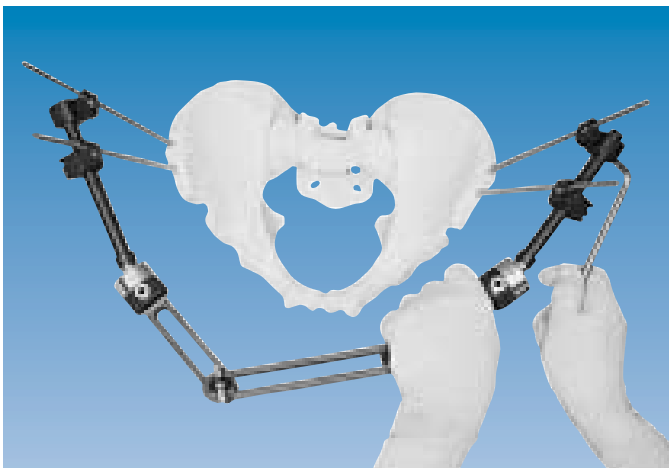
The procedure is then repeated on the opposite side. The fixator is applied and reduction carried out.



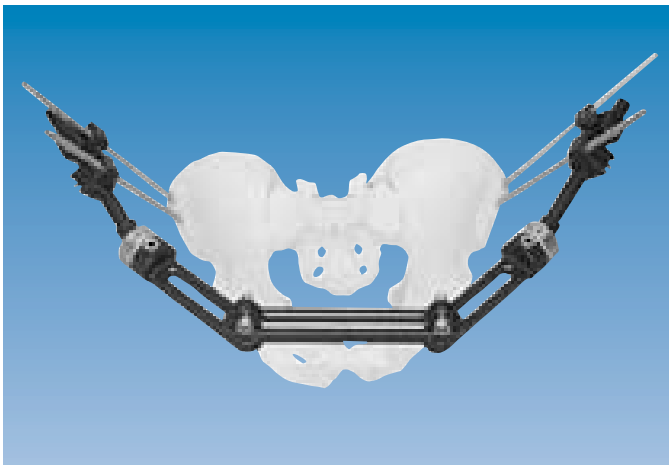
Application with Ball-Jointed Modules for Independent Screw Placement

Since the iliac crest is a curved structure, some surgeons may wish to have the option of placing screws other than parallel to one another in a straight line. Thus, they may choose to insert screws in the center of the crest where there is superior bone stock, and at angles which will allow them to find the ideal path between the inner and outer tables of the ilium. This may be achieved using Ball-Jointed Modules for Independent Screw Placement.

Where these modules are used, screws are inserted freehand through a screw guide in the preferred positions.



They are then introduced into independent screw clamps (10055) which are locked both to the screws and to the bar of the Ball-Jointed Module on which they slide, by a single nut.



Reduction is then carried out in the usual manner (see pages 8-10).

During the immediate post-operative period, hemoglobin levels and hemodynamics should be carefully monitored, which is routine in multiple trauma victims. Should the patient continue to lose blood, and other sources of bleeding have been excluded, arteriography should be carried out within 6 hours of fixator application.

Under ideal circumstances, the angiography suite should be equipped with the means of embolizing the ruptured vessels. The value of MAST trousers has not been proven under these circumstances, and adverse effects have been reported. If the patient requires to be turned on either side, preference is given to the uninjured hemipelvis.

Physiotherapy

Since physiotherapy should be started on day one in these patients to help to prevent the sometimes lethal complication of deep vein thrombosis, there will be considerable movement of the skin around the screws. Daily changes of dressing are necessary and the incision should be checked to determine whether it is generous enough or whether it rubs against the screws. If this is the case, it must be enlarged. Physiotherapy should continue with the patient being allowed to sit up, if possible, after one week and mobilization with partial weightbearing in a walking frame is carried out after three weeks.

Frame Removal

The fixator is expected to remain in place for a minimum of six weeks or until union, in bony injuries of the anterior pelvic ring, and for nine weeks in lesions of the symphysis pubis. At the end of the treatment period the fixator body is removed first, leaving the screws with the clamps in situ. Mobilization is continued and if no pain or discomfort is experienced by the patient, clamps and screws may be removed after one week. If pain persists, the fixator body should be reapplied for a further three weeks.

Pin Site Care

The visible parts of the screws and surrounding skin should be cleaned on the day following application of the Dynamic Axial Fixator and at least once a day thereafter. Only sterile water should be used for this purpose. A dry absorbent dressing with additional gauze is used around the pin sites. After a few days, when they are dry, no dressing is needed.

There may be some drainage of clear fluid especially in overweight patients. This should not be mistaken for infection and is not a true complication. It may be the result of excessive patient mobility and subsequent irritation of the tissues around the screws. Normal care on pin cleaning is required.

Where inflammation is seen and the exudate is purulent, with the skin around the screw red and warm, a bacteriological swab should be taken and the appropriate antibiotic given for about a week. In the presence of a colostomy, the pin sites should be supervised very closely to detect any signs of incipient infection which, if it occurs, should be treated aggressively.

Weightbearing should be restricted until resolution has occurred.

A. INTRA-OPERATIVE COMPLICATIONS

Possible Complications	Recommended Actions
Injury to the lateral femoral cutaneous nerve or a branch of the circumflex artery.	This may be avoided by using blunt dissection down to the bone and protecting structures at risk with Langenbeck retractors.
Poor purchase of the bone screws in the pelvis.	The screw or screws should be removed and re-sited.
Inadequate reduction of the pelvic ring achieved.	Assess for posterior pelvic ring pathology (CT scan), and if this is absent, check for possible interposition of bladder or other soft tissues in the symphysis pubis.

B. POST-OPERATIVE COMPLICATIONS

Possible Complications	Recommended Actions
Insufficient distance between fixator body and skin, a situation which, if not corrected, could predispose to pressure sores in regions of contact.	Loosen clamp screws and slide fixator away from skin surface. Re-tighten clamp screws to establish fixator in its new position.
Pin track infection.	Enlarge skin and soft tissue incision around screw or screws involved and follow procedures outlined under “Pin Site Care” (see page 12).
Bone osteolysis at pin site.	Remove and resite screw.
Pain during mobilization.	Check for posterior pathology (CT scan). Decrease weightbearing temporarily.
Signs of peripheral edema and pain.	Check for DEEP VEIN THROMBOSIS, and if present, treat accordingly.
Colostomy required, increasing the risk of contamination of pin sites by fecal organisms.	Protect pin sites at all times with appropriate dressings.
Draining sinus after screw removal.	Surgical exploration and debridement of the sinus.

Anterior external fixation is an integral part of the resuscitation of multiple trauma victims. The ideal place for the fixator to be stocked is the emergency resuscitation area and the device is suitable for this, since no power instrumentation is required for its application. The stability provided by the Orthofix fixator has been proven by mechanical studies and its three dimensional reduction capacity has been demonstrated above. However, the fixator in the anterior position only replaces the tension band effect of the pubic rami and the symphysis pubis. It cannot control a significant posterior instability and for this, the steps outlined below must be followed.

To assess posterior pathology, CT scanning and examination under fluoroscopy are mandatory. CT scanning does not necessarily have to be carried out on the day of the injury, but should be performed over the next few days. At this point it is important to decide whether the patient can be dealt with within the receiving institution or whether referral of the patient is advisable.

Without familiarity in fixation of the posterior pelvic ring, the results in vertically or horizontally unstable posterior injuries will be less favorable (Tile, 1988).

To assess posterior pathology, the CT scan should encompass the full range from the fifth lumbar vertebra downwards. Injuries of the posterior ring can involve the SI joints, vertical fractures of the sacrum and/or an intra-articular fracture of the ilium.

All of these injuries require separate techniques which are available on request.

Posterior surgery should not be delayed for more than six to eight days. If delayed any longer, bone formation will commence, especially in those cases where head injury is present. Under such circumstances, reduction of a vertical displacement or a horizontal displacement may become exceedingly difficult. The resultant leg length discrepancy and/or the neurological complications encountered will significantly influence the outcome.

- DE BASTIANI G., ALDEGHERI R., RENZI-BRIVIO L. The treatment of fractures with a Dynamic Axial Fixator. *J. Bone Joint Surg.*, 1984; 66-B: 538-545.
- BELL A.L., SMITH R.A., BROWN T.D., NEPOLA J.V. Comparative Study of the Orthofix and Pittsburgh Frames for External Fixation of Unstable Pelvic Ring Fractures. *Journal of Orthopaedic Trauma*, 1988; 2 (2): 130-138.
- BUCHHOLZ R.W. The pathological anatomy of Malgaigne fracture dislocations of the pelvis. *J. Bone Joint Surg.*, 1981; 63-A: 400-404.
- HAESKE-SEEBERG H. (1988) Inaugural Dissertation, Westfälische Wilhelms - Universität Münster.
- HESP W.L., VAN DER WERKEN C., KEUNEN R.W., GORIS R.J. Unstable fractures and dislocations of the pelvic ring: results of treatment in relation to the severity of injury. *Netherlands Journal of Surgery*, 1985; 37: 148-152.
- MALGAIGNE J.F. *Treatise in Fractures*. Philadelphia; Lippincott (1859).
- MARTIN J.G., NEPOLA J.V., MARSH J.L. The treatment of unstable pelvic injuries with the Orthofix external fixator. Supplement to *International Journal of Orthopaedic Trauma*, 1993; 3(3): 49-51.
- MEARS D.C., FU F.H. Modern concepts of external skeletal fixation of the pelvis. *Clinical Orthopaedics*, 1980; 151: 65-72.
- MÜLLER-FÄRBER J., MÜLLER K.H. Die verschiedenen Formen der instabilen Beckenringverletzungen und ihre Behandlung. *Unfallheilkunde*, 1984; 87: 441-445.
- PAUWELS F. *Gesammelte Abhandlung zur funktionellen Anatomie des Bewegungsapparates*. Berlin; Springer-Verlag (1965).
- PENNIG D., KLEIN W., BRUG E. Pelvic ring disruption. In *External Fixation and Functional Bracing, 191-195*. Editors Coombs R., Green S., Sarmiento A. (1989). Orthotext, England.
- PENNIG D. The place of anterior external fixation in the stabilization of pelvic ring disruptions. Supplement to *International Journal of Orthopaedic Trauma*, 1993; 3 (3): 44-48.
- PENNIG D., GLADBACH B., MAJCHROWSKI W. Pelvic Ring Disruption following Spontaneous Childbirth. *J. Bone Joint Surg. (Br)*, 1997; 79B: 438-440.
- PENNIG D., GAUSEPOHL T. External Fixation in Pelvic Ring Injuries: the Pelvic Fixator. *Orthofix External Fixation in Trauma and Orthopaedics*. G. De Bastiani, A.G. Apley, A. Goldberg (Eds), Springer 2000; 219-235.
- RIEGER H., PENNIG D., BRUG E., BÜNTE H., KRINGS W. Beckenringverletzung und Bauchtrauma. *Unfallchirurg.*, 1991; 94: 110-115.
- SCHWEIBERER I., DAMBE L.T., KLAPP F. Die Mehrfachverletzung: Schweregrad und therapeutische Richtlinien. *Chirurg.*, 1978; 49: 608-614.
- SLÄTIS P., HUITTINEN V.M. Double vertical fractures of the pelvis. *Acta Chirurgica Scandinavica*, 1972; 138: 799-807.
- TILE M. *Fractures of the Pelvis and Acetabulum*. Baltimore; Williams and Wilkins (1984).
- TILE M. Pelvic ring fractures: should they be fixed? *J. Bone Joint Surg.*, 1988; 70-B: 1-12.

EXTERNAL FIXATION

- PM 010 ORTHOFIX EXTERNAL FIXATION:
BASIC CONSIDERATIONS
- PM 020 GROWTH PLATE DISTRACTION
 - Chondrodiatasis
 - Hemichondrodiatasis
- PM 030 LIMB LENGTHENING AND CORRECTION OF
DEFORMITIES BY CALLUS DISTRACTION
 - Callotasis
 - Hemicallotasis
 - Tibial lengthening and angular correction with
the OF-Garches limb lengthener
- PM 040 ARTHRODIATASIS (Articulated Joint Distraction)
 - Hip
 - Ankle
- PM 050 ARTHRODESIS (Joint Fusion)
 - Shoulder
 - Hip
 - Knee
 - Ankle
- PM 060 DIAPHYSEAL FRACTURES
 - Humerus
 - Forearm
 - Femur
 - Tibia
- PM 070 DISTAL TIBIAL AND PILON FRACTURES
- PM 080 PELVIC APPLICATIONS
- PM 090 TREATMENT OF FRACTURES AND
DEFORMITIES IN SMALL BONES
- PM 100 THE PENNIG DYNAMIC WRIST FIXATOR
- PM 110 THE LIMB RECONSTRUCTION SYSTEM
 - Part A: General Principles
 - Part B: Correction of Deformities
- PM 120 THE RING FIXATION SYSTEM
 - Part A: The Hybrid Fixator
 - Part B: The Sheffield Ring Fixator -
Standard Trauma Applications
 - Part C: The Sheffield Ring Fixator -
Limb Reconstruction and Complex Trauma

INTERNAL FIXATION

- PM IKD Intramedullary Skeletal Kinetic Distractor:
Tibial Surgical Technique
- Intramedullary Skeletal Kinetic Distractor:
Femoral Surgical Technique
- PM IMT The Orthofix Tibial Nailing System
- PM IMF The Orthofix Femoral Nailing System
- PM AAN The Ankle Arthrodesis Nail
- PM RFN The Retrograde Femoral Nailing System
- PM PRD PORD™ DEVICE
Posterior Reduction Device for Hip and Femoral
Fractures
- PM PCP THE GOTFRIED PC.C.P
for Percutaneous Compression Plating of Pertrochanteric
Hip Fractures

**Orthofix wishes to thank the surgeons listed below
for their invaluable help in the preparation of this manual:**

Prof. Dr. D. Pennig

St. Vinzenz-Hospital
Köln - Germany

Dr. L. Renzi-Brivio

Ospedale Carlo Poma
Mantova - Italy

Your Distributor is:

www.orthofix.com



ORTHOFIX - Wonersh House - The Guildway - Old Portsmouth Road
Guildford - Surrey GU3 1LR - England
Tel. 44 1483 468800 Fax 44 1483 468829