

Copeland
shoulder



Copeland Shoulder™
Operative **Technique**

Clinical References

1. J Shoulder Elbow Surgery Volume 14, Number 2 2005
Geometrical Analysis of Copeland Surface Replacement Shoulder Arthroplasty in Relation to Normal Anatomy
Simon R Thomas, MRCS, Giuseppe Sforza, MD, Ofer Levy, MD, MCh(Orth), and Stephen A. Copeland FRCS Reading United Kingdom
2. The Journal of Bone & Joint Surgery Vol 86-B, 2004, Supplement I
Orthopaedic Proceedings - British Elbow and Shoulder Society (Wrightington Hospital, Lancashire, 15/16 May 2003)
The Cemented Copeland Shoulder Hemiarthroplasty - A Clinical And Radiological Review
A Ali, NADla, SA Shahane, O Stanley Department of Orthopaedics, Sheffield Teaching Hospitals NHS Trust, Northern General Hospital, Sheffield
3. The Journal of Bone & Joint Surgery Vol 86-A, Number 3, March 2004
Copeland Surface Replacement Arthroplasty Of The Shoulder In Rheumatoid Arthritis
Ofer Levy, MD, MCH(ORTH), Lennard Funk, MSc, FRCS (Tr and Orth), Giuseppe Sforza, MD, and Stephen A Copeland, FRCS Investigation performed at Reading Shoulder Unit, Royal Berkshire Hospital, Reading, United Kingdom
4. Techniques in Shoulder & Elbow Surgery Vol 4, Issue 4, 2003
Resurfacing Arthroplasty Of The Shoulder
Stephen A Copeland, FRCS, Ofer Levy, MO and Harry C Brownlow, FRCS
Reading Shoulder Unit, Berkshire Independent Hospital, Berkshire, United Kingdom
5. SECEC 2002 -Budapest (Presentation)
Geometrical Analysis Of The Copeland Cementless Surface Replacement Shoulder Arthroplasty With Correlation To Clinical Outcome
Thomas SRYW, Sforza G, Levy O, Copeland SA The Reading Shoulder Surgery Unit, The Royal Berkshire Hospital, London road, Reading, RG1 5AN United Kingdom
6. SECEC 2002 - Budapest (Presentation)
Surface Replacement Arthroplasty For Avascular Necrosis Of The Humeral Head
Kouty E, Funk L, Levy O, Copeland SA
The Reading Shoulder Surgery Unit, The Royal Berkshire Hospital, London road, Reading, RG1 5AN, United Kingdom
7. SECEC 2002 -Budapest (Poster)
Copeland Hemiarthroplasty Of The Shoulder
Wilson A, Chambler A, Thomas S, Harding I, Thomas M
Heatherwood and Wexham Park Hospitals Trust, Wexham, Slough, Berkshire, Windsor, United Kingdom
8. The Journal of Bone & Joint Surgery Vol 83-B, Number 2, March 2001
Cementless Surface Replacement Arthroplasty Of the Shoulder 5 To 10-Year Results With The Copeland Mark-2 Prosthesis
a Levy, S A Copeland Royal Berkshire Hospital, Reading, England
9. Master Techniques In Orthopaedic Surgery The Shoulder (Second Edition)
Editor - Edward V Craig Series Editor - Roby C Thompson, JR
Part V -Arthroplasty And Arthroplasty Alternatives Surface-replacement Arthroplasty Of The Shoulder
Stephen Copeland
10. 7th ICSS International Congress on Shoulder Surgery, Sydney, Australia, 1998.
Cementless Surface Replacement Arthroplasty of the Shoulder -11 - Years Experience.
Levy O, Williams H, Bruguera J, Kelly C and Copeland SA
Institution Department of Shoulder Surgery, Royal Berkshire Hospital, Reading, United Kingdom
11. The Antero-superior Exposure for Total Shoulder Replacement
Donald B. Mackenzie, Port Elizabeth, Eastern Cape Province, South Africa



Disclaimer

The following are the opinions and surgical practice of Mr S A Copeland, FRCS, Consultant Orthopaedic Surgeon at the Royal Berkshire Hospital, Reading, England, U.K. and not Biomet UK Ltd.

This Operative Technique was written in conjunction with Mr S A Copeland and Mr O Levy at the Royal Berkshire Hospital, Reading, England, U.K.

Biomet UK Ltd, as the manufacturer of this device, does not practice medicine and does not recommend any particular surgical technique for use on a specific patient. The surgeon who performs any implant procedure is responsible for determining and utilising the appropriate techniques for implanting the prosthesis in each individual patient.

Biomet UK Ltd, is not responsible for selection of the appropriate surgical technique to be utilised on an individual patient.

© Biomet UK Ltd 2005

Clinical Background

Copeland



Cementless Surface Replacement Arthroplasty (CSRA) of the shoulder differs in many ways from nonconstrained stemmed shoulder prostheses. The design concept is to replace damaged joint bearing surfaces and restore normal anatomy with minimal bone resection.

Historically, the early development of shoulder arthroplasty in Europe was associated with constrained designs of prostheses to cope with the problems of massive tissue loss secondary to infection and tumour. In the USA, Neer developed a stemmed unconstrained prosthetic replacement of the proximal humerus specifically to deal with the problems of acute four-part fractures. His stemmed unconstrained design of prosthesis was successful in providing a scaffold to rebuild the fractured proximal humerus. Only later was this used for arthritis and a glenoid prosthesis developed. Neer's design of a stemmed humeral component was very similar to that very widely used for hip replacement. Neer had shown convincingly that the prosthetic shoulder joint did not need to be mechanically constrained.

Neither of these development paths were specifically directed to produce a design for use in shoulder arthritis.

In the early 1980's the idea of developing a shoulder joint specifically for use in the less destroyed arthritic shoulder using a surface replacement arthroplasty was introduced.

It seemed illogical and unnecessary to use a stem if the tuberosities and rotator cuff were intact.

The Copeland Shoulder Prosthesis was designed to address these problems. It offers cementless fixation, requires minimal bone removal, and is a surface replacement technique so that joint arthroplasty can now be considered for the less destroyed shoulder. It has been in clinical use since 1986.

The Copeland Shoulder or Cementless Surface Replacement Arthroplasty (CSRA) of the shoulder was developed by Mr S A Copeland, FRCS Consultant Orthopaedic Surgeon at the Royal Berkshire Hospital, Reading, England, U.K.

Design Concept

Anatomic considerations - Resurfacing to normal anatomy

Surface Replacement

The aim of the design was to mimic anatomy as closely as possible. In essence, in arthritis, the joint bearing surfaces are damaged. To replace this damaged surface is the ideal goal with minimal interference. Eight sizes of prostheses have now been developed.

Minimal Bone Removal

We have held to the principle that bone stock should be preserved whenever possible. The experience of replacement arthroplasty at both the hip and the knee indicates that no matter how successful the prosthesis, a few are going to fail and require revision. Too often, loss of bone stock has called for larger prostheses and more cement. Only relatively recently has the concept of impaction bone grafting and trying to preserve bone stock been realised. In this design, bone removed for the central drill hole for the prosthesis is used for grafting any defects under the humeral cap so no bone is wasted at all. If the prosthesis were to fail only the amount of bone that lies under the humeral cap would be lost which would be the normal amount of bone removed when inserting a standard stemmed humeral prosthesis.

Cementless

Experience with hip and knee replacement has led us to believe that the use of cement may not be optimal. No matter how good the cementing techniques, should infection or loosening occur, then bone loss can be unpredictable and considerable. In this prosthesis the implants are fixated with an impact fit taper peg and the inner side of the fixed prosthesis and the peg are Hydroxyapatite coated.


Anatomical Design/Geometry

Although the actual variation in size of glenoid and humeral head is not wide, the variations in version and geometry are huge. Variation in version shaft angle can vary greatly. The most important geometric variation is the posterior offset. The humeral head is not centred on the humeral shaft but offset posteriorly and medially by approximately 5mm. Hence, if a stemmed prosthesis is centred on the humeral shaft then the humeral head will not lie in an anatomical position unless it is specifically made for a left or right shoulder. Recent prosthetic design has allowed for this huge variation in morphology at the proximal end of the humerus by modular design. They are also built around a humeral cemented stem. If a surface replacement is used no complicated instrumentation is necessary to calculate angles of version, inclination or offset. The surface replacement is literally put in situ to replace the bearing surface. The offset occurs automatically and the varus angulation is determined from the original anatomical neck, which can be seen at the time of operation. This does not require complicated instrumentation to mimic the exact anatomy.

Introduction

Lateralisation of Centre of Rotation

Erosion by the arthritis distorts the anatomy. This can occur in many different forms. Erosion may be asymmetric, anterior or posterior and may be more on the humeral or the glenoid side but the net effect is to medialise the centre of rotation. Medialisation has a secondary effect of relatively lengthening both rotator cuff and deltoid. One of the aims of shoulder replacement must be to try and regain shoulder geometry and lateralise the centre of rotation. This may be an unrealistic goal. With gross and longstanding medialisation of the shoulder if the centre of rotation is suddenly lateralised, this leaves the adapted soft tissues too short. The approach is usually anterior with subscapularis being divided. Even with lengthening this may lead to difficulty in closing subscapularis or closing it with some degree of internal rotation. Closure on the operating table must allow for some external rotation. If there is a fixed internal rotation deformity then posterior translation forces will occur and posterior subluxation will result. Regaining an anatomical lateralisation of centre of rotation may not be possible. This has already been shown using different modular prostheses. Overstuffing of the joint presents its own problems and normal anatomical geometry may be impossible to achieve. Lateralisation although a desirable aim is often a compromise. It can be seen from the modular joints that although there may be many sizes available, very few sizes are actually used in practice. With surface replacement, the erosion is accepted and a new surface placed on the eroded surface. Different thickness of glenoid component are available if further lateralisation is deemed necessary as with the modular prostheses, these have rarely been found to be of use in the practical situation.



Simple Instrumentation

Any procedure if it is to be successful, must be reliable and reproducible. The more complicated the instrumentation, the more scope for error in their use. Although most shoulder replacements are performed in specialised centres, a high proportion of shoulder replacement is done by surgeons who may do only a few replacements a year. Hence, complicated instrumentation may not be available to them on the grounds of cost and because of unfamiliarity of use may lead to wrong usage. Simple instrumentation was developed to shape the joint surfaces and to implant the prosthesis.

Introduction

Clinical Experience

Clinical experience¹ of the Copeland Cementless Surface Replacement Shoulder Arthroplasty now spans nearly 20 years. Between 1986 and 1997, Surface Replacement Arthroplasties were performed for the treatment of Osteoarthritis, Rheumatoid Arthritis, AVN, Instability arthropathy, post traumatic arthropathy and Cuff arthropathy. The best results are achieved in primary Osteoarthritis with Constant scores of 93% for TSR and 91% for Hemiarthroplasty.

In Rheumatoid Arthritis Constant scores of 76% for TSR and 71% for Hemiarthroplasty.

The poorest results were encountered in patients with cuff arthropathy and post traumatic arthropathy with adjusted Constant Scores of 58% and 61% respectively.

Active elevation improved by an average of 55° to an average of 124° for Osteoarthritis, AVN, and Instability arthropathy and to an average of 103° for Rheumatoid Arthritis. For post traumatic arthropathy and Cuff arthropathy to an average of 93° and 74°, respectively. Pre-operative and post-operative differences were statistically significant for all the disease groups ($p < 0.001$).

93.6% of patients considered their shoulder had been made much better or better due to operation (See references).

Radiographic results

No lucencies or loosening have been observed in the Hydroxyapatite coated implants since its introduction in 1993.

Revision Rates and Revision Surgery

The overall revision rate for the whole diagnostic series from 1993 is 2.66%. Primary osteo arthritis has been the commonest indication for surgery and in this group the overall revision rate has been 0.71%.

Because we have demonstrated no statistical difference between the outcomes of total replacement hemi-arthroplasty we most frequently do hemi-arthroplasty alone.

The results of surface replacement hemi-arthroplasty appear better than stemmed hemi-arthroplasty. It is thought that this is because of better replication of anatomy.

This series of results are at least comparable and in line with those reported in the literature concerning stemmed prostheses with comparable length of follow-up. Using the Copeland Cementless Surface Replacement Arthroplasty prosthesis, several severe complications mainly concerning the humeral shaft and periprosthetic fractures can be avoided.

Should the need for revision surgery or arthrodesis arise, these procedures are easily performed as bone stock has been maintained and no loss of length encountered. It does seem that the humeral component does not need a stem or cement for fixation.

Patient Positioning

Pre-operative preparation and patient positioning

Pre-operative prophylactic antibiotics should be given intravenously either one hour prior to surgery or at the time of anaesthetic induction. In patients who are not sensitive to iodine a skin pre-preparation using povidone iodine is performed in the ward prior to surgery.

A povidone iodine soaked surgical dressing is placed into the axilla, which may be clipped no more than 6 hours before the operation.

The patient should be placed in a semi sitting or beach chair position at about 45 degrees of head-up tilt with the head on a neurosurgical headpiece and the arm on a short arm board attached to the side of the operating table. It is important to have the patient close to the edge of the table and the short arm board to permit hyperextension of the arm during surgery to allow delivery of the humeral head into the anterior wound and to facilitate insertion of the humeral component. The shoulder blade is best stabilised by placing a small (500ml) plastic infusion bag or a sandbag under the medial border of the scapula.

Routine antiseptic preparation of the skin of the whole of the arm is carried out. The preparation is continued as far proximally as the ear and as far distally as the breast. The preparation should also be carried out as far medially as the midline anteriorly and as far as the infusion bag or sandbag posteriorly. The forearm and arm should be covered with a sterile stockinette and either an upper limb isolation drape or a "U" drape should be used to provide a safe sterile field. An adhesive plastic sterile drape is then applied and will ensure the drapes do not "migrate" during the operation.

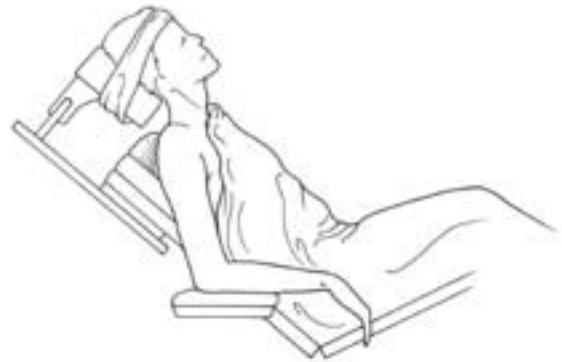

fig 1

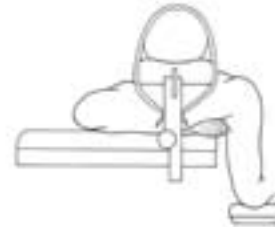


fig 2

Surgical Incision - *Option A*

Deltopectoral approach

Access

This approach provides an exposure of the front of the glenohumeral joint, the upper humeral shaft and the humeral head.

Incision

A 15 cm incision is made from the clavicle down across the tip of the coracoid and continued in a straight line to the anterior border of the insertion of the deltoid. (Fig. 3)

Approach

The cephalic vein is mobilised lateral in the deltopectoral groove. The vein is retracted laterally with the deltoid. The arm is abducted 40° to 60°. The clavipectoral fascia is incised. The subacromial space is cleared and a broad elevator is placed beneath the acromion as a retractor. At this stage improved exposure will be obtained by dividing the proximal 2 cm of the insertion of pectoralis major (Fig. 4).

The shoulder is flexed and externally rotated to facilitate coagulation of the anterior circumflex humeral vessels. It is very important at this stage to insert stay sutures into the subscapularis muscle to control retraction (Fig. 5). The tendon is divided 2 cm medial to the bicipital groove. If the subscapularis appears tight it should be divided in an oblique or "Z" manner to allow repair with lengthening of the tendon.

The joint capsule is then released anteriorly and inferiorly whilst taking care to protect the axillary nerve with a blunt elevator where it passes through the quadrilateral space. The glenohumeral joint may now be dislocated anteriorly by external rotation and extension, allowing a full exposure of the humeral head and neck.

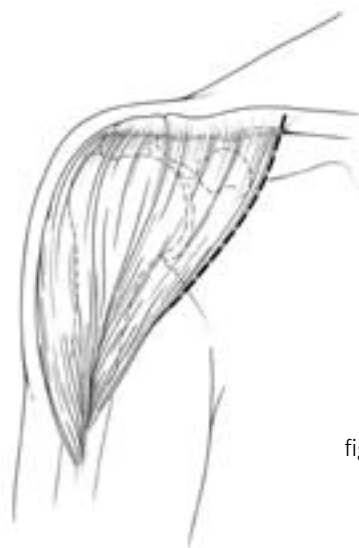

fig 3

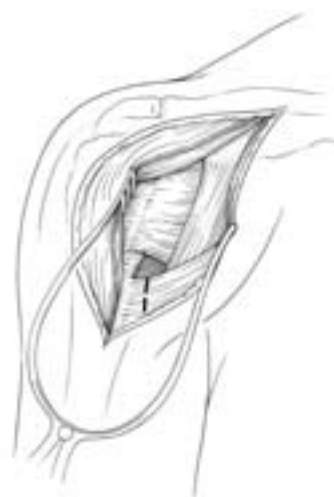

fig 4

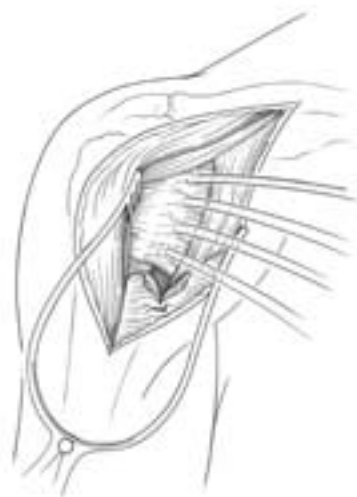

fig 5

Surgical Incision - *Option B*

Antero-superior “Mackenzie²” approach

Access

This approach provides an exposure of the Gleno-humeral joint, the humeral head and the tuberosities, as well as exposure of the acromion and AC joint.

Incision

The skin incision extends distally in a straight line from just posterior to the acromioclavicular joint for a distance of 9 cm (Fig. 6).

Approach

The anterior deltoid fibers are split for a distance of not more than 6 cm, and a loose No. 1 stay suture is placed in the distal end of the split to prevent further extension and possible injury to the axillary nerve. The acromial attachment of the deltoid is lifted with an osteo-periosteal flap to expose the anterior acromion and preservation of the superior acromioclavicular ligament (Fig. 7).

An anterior acromioplasty according to the technique of Neer is performed.

If further exposure is needed, then excision of the lateral end of 1 cm of clavicle considerably enhances this.

On both approaches:

The rotator interval is identified and longitudinally incised along the line of the long head of biceps to identify the exact insertion of subscapularis. Subscapularis is held by stay sutures and disinserted (Fig. 8). The shoulder is dislocated anteriorly. Long head of biceps, if intact, is dislocated posteriorly over the humeral head (Fig. 9).

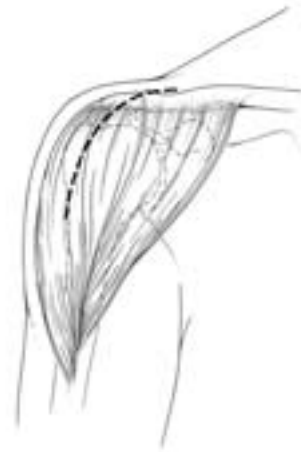

fig 6

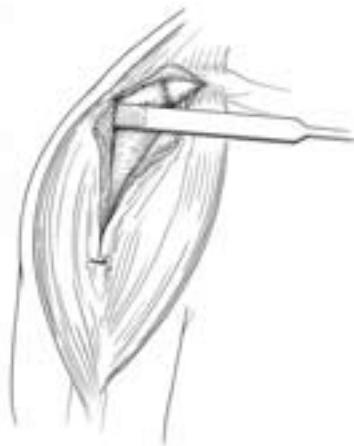

fig 7

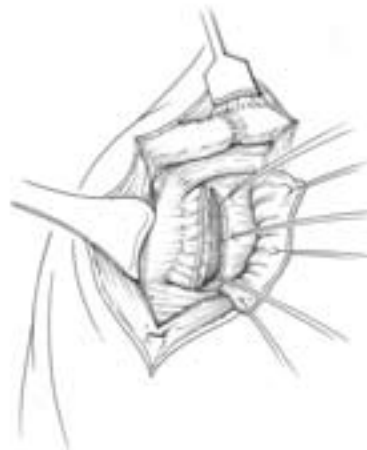

fig 8

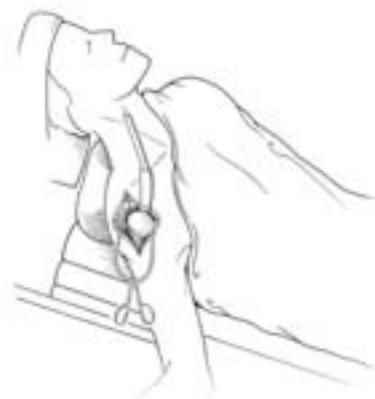

fig 9

Preparation of the Humeral Head

The anatomical neck of humerus is defined (the line of insertion of the cuff and capsule). This is important to determine the exact neck shaft angle. Osteophytes are nibbled away from the superior and the anterior aspect of the humeral neck with further external rotation and positioning of the arm extensive inferior osteophytes can be removed. The pre-operative radiographs are helpful to assess the extent of these osteophytes.

Anterior osteophytes often contribute to loss of external rotation by relatively shortening subscapularis. Removal of these osteophytes also allows better positioning and rotation of the head to gain access to the posterior and superior osteophytes that also need removal. It is stressed at this stage that removing these osteophytes is essential to determine the anatomical neck and not to shape the humeral head which is done by the humeral shaper.

(Fig. 10) The humeral drill guide determined by the pre-operative planning is then placed on top of the humeral head. The free edge of the humeral drill guide is placed parallel to the anatomical neck. This automatically places the prosthesis in the anatomical position. The drill guide is assessed for anterior / posterior placement and placed in the centre of the humeral head. This automatically builds in the anatomical degree of retroversion and inclination.

(Fig. 11) A guide wire is then passed down the humeral drill guide into the humeral head. The degree of retroversion can be checked between the angle of the Kirschner wire in relation to the forearm flexed at 90°. There is no fixed degree of version attempted but purely reproduction of the anatomical version (this can vary from 5° to -55°).

(Fig. 12) The humeral drill guide is removed and the position of the guide wire checked that it is anatomical and central in the humeral head. The cannulated humeral surface cutter is then used to shape the humeral head. The cutter has a safety mechanism whereby it will only resect 3mm of bone per application.

Whilst the the reamer is rotating, light pressure on the humeral head will Engage the cutting teeth and the surgeon will observe that while it is rotating, bone appears through all the holes in the surface cutter. This ensures complete bony apposition up to the undersurface of the prosthesis. The surface cutter also delineates the edge of where the prosthesis will come and digs into the bone at this level by the teeth on the free edge of the cutter. This marks further bone to be removed from the periphery of the head with a small osteotome or bone nibblers.

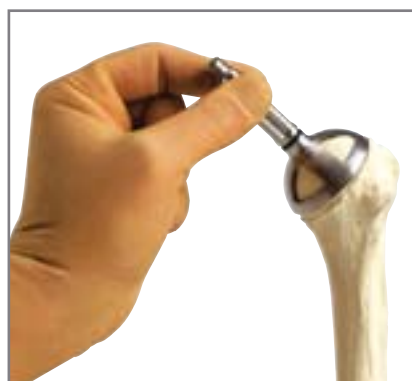

fig 10

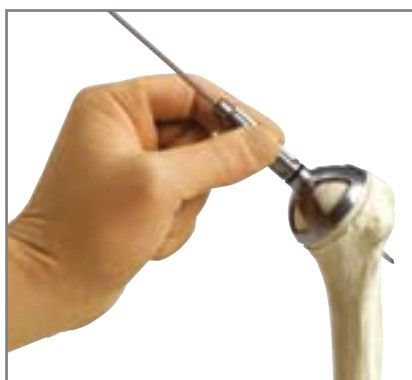

fig 11

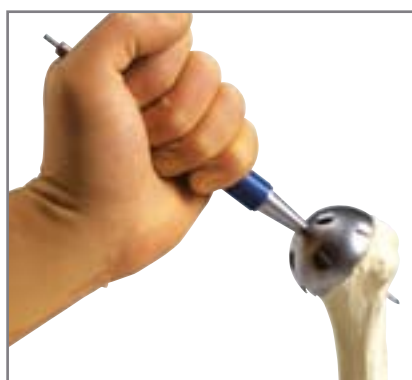

fig 12

The edge of this cut will now appear beneath the normal surface of the bone. It is intended that the depth of the prosthesis will build this up to the normal anatomical surface of the bone.

(Fig. 13) The cannulated humeral stem cutter is passed over the guide wire and, with a power drill, the central pilot hole is made down to the shoulder of the cutter. The cutter and guide wire are removed. All morselised bone generated by making this drill hole is saved for later grafting and mixed with scavenged patients blood from wound.

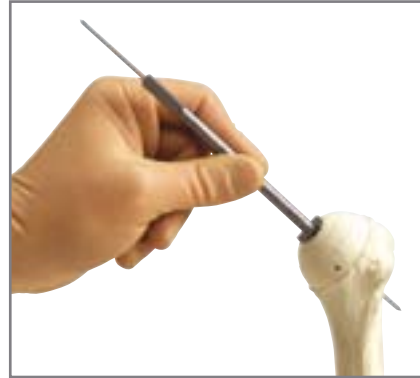

fig 13

(Fig. 14) The trial humeral prosthesis is then inserted into the pilot hole and a trial reduction made. If it is intended that only a hemiarthroplasty is to be done then stability at this time can be tested and range of motion, i.e. that the hand can easily go to the opposite axilla and at least 30° of external rotation can be achieved before anterior translocation. The prosthesis is also checked for stability in flexion/extension and abduction.

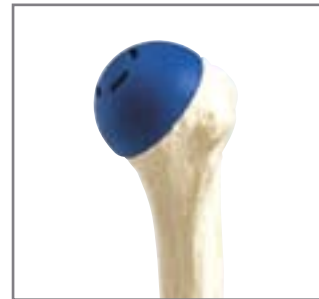

fig 14

(Fig. 15) If the surgeon desires, the new cannulated instruments can be used in a identical fashion to the older instruments i.e. using the spade cutter to create the peg hole before reaming the humeral head. This is achieved by inserting the trial humeral peg into the selected reamer and proceeding in the same fashion as the older instrument set.

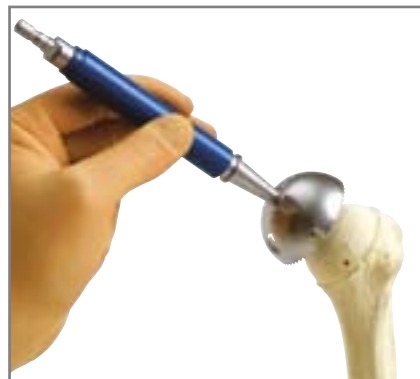

fig 15

(Fig. 16) Additionally if recutting of the humeral head is required after the trial Reduction the humeral spade trial can be inserted into the hole created by the spade cutter in the humeral head and the caunnlated reamer re-applied over the attached guide wire.

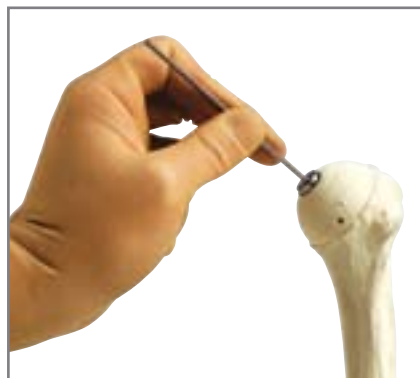


fig 16

Preparation of the Glenoid [TOP TRAY]

The trial humeral cap is left in situ so that the prepared humeral head is not deformed by subsequent retraction. A Bankart skid or Fukuda retractor is used to sublax the humeral head postero-inferiorly for glenoid exposure. This step is more difficult than in a standard prosthesis. No bone has been removed from the humeral head and therefore access to the glenoid face is more restricted. An extensive capsulotomy must be made. The capsule is incised at the glenoid neck anteriorly, inferiorly and posteriorly (Fig. 16). Once this has been done adequate exposure of the glenoid can be made. The glenoid drill guide for the correct side is inserted to determine the exact centre of the glenoid. A bone spike is passed down the posterior aspect of the glenoid neck to determine the line of the scapula. A guide wire is passed through the central hole in the glenoid drill guide into the central body (Fig. 17). This is not necessarily at right angles to the arthritic surface of the glenoid. Asymmetric erosion may have occurred and needs to be assessed. Pre-operative imaging (axillary view radiograph and CT) is helpful in this regard.

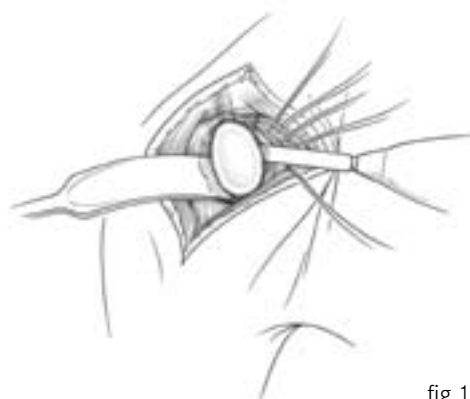

fig 16

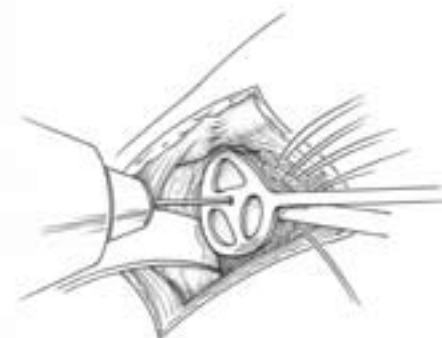


fig 17

A cannulated glenoid stem cutter is passed over the Kirschner wire and the central pilot drill hole made. All bone generated by making this hole is saved for later grafting (Fig. 18).

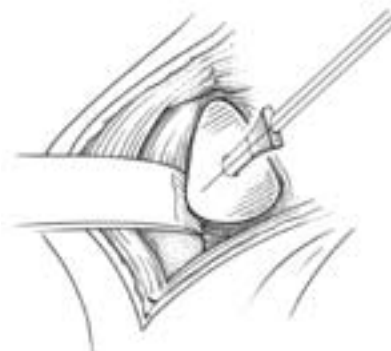

fig 18

The glenoid articular surface is prepared with the glenoid surface cutter placed in this pilot hole (Fig. 19).

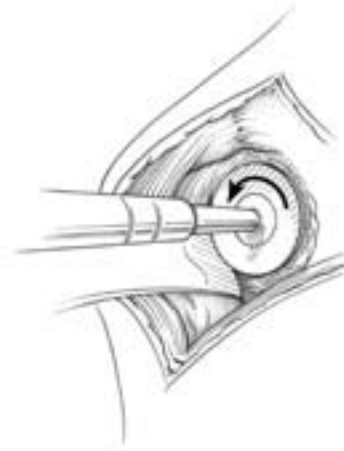

fig 19

If glenoid erosion is severe anterior or posterior, grafting may be required but this is rare. The trial glenoid component is inserted and then a trial reduction of both components to assess stability and range of movements is made (Fig. 20).

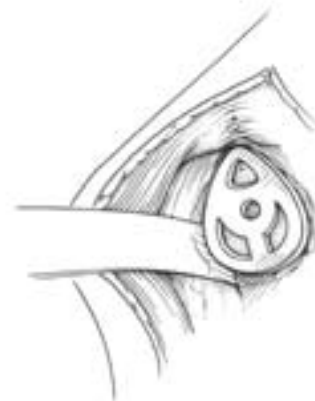

fig 20

Insertion of the Components

In primary and secondary osteoarthritis as much of the sclerotic surface of bone is retained as possible to provide a good solid seating for the prosthesis. However, because the prosthesis is HA coated, the surface needs to be made reactive to allow bony ingrowth by drilling the surface with a fine drill. Multiple shallow drill holes are made to perforate the sclerotic surface down to bleeding bone (Fig. 21).

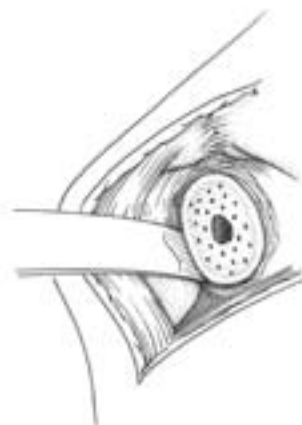

fig 21

The fragments of bone from the drilling are left in situ, and the bone preserved from the pilot drill holes is placed on the back of the glenoid prosthesis (Fig. 22). The prosthesis is inserted in the pilot hole and under finger pressure will pass two-thirds down the locating stem. The glenoid component is impacted in place such that the prosthesis is flush with the surface of the bone. Several small taps of the mallet only are necessary. Positioning and solidity of the prosthesis is checked. The trial humeral component is now removed and the humeral head viewed. Again, if the surface is hard sclerotic bone then this is again drilled with multiple fine 2mm drill holes to make the surface reactive (Fig. 23). The remaining bone from the drill holes are left in situ and the bone saved from the initial pilot drill hole is mixed with the patients blood to form a paste which is smeared onto the back of the prosthesis before insertion and irregularities in the humeral head routinely grafted using bone from osteophytes which had previously been removed. The humeral prosthesis is impacted so that the humeral prosthesis is flush against the bone. Any excess graft may be seen to extrude from the base of the prosthesis. The joint is reduced and again stability tested.

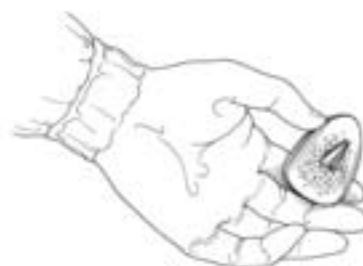

fig 22

Applying tension to the subscapularis stay sutures, the position of re-attachment of subscapularis is assessed. Usually because of lateralisation of the centre of rotation an attempt is made to gain relative length in subscapularis. This can be gained in two ways: (1) by the stepwise cut in subscapularis when entering the joint and (2) by medialisation of the insertion of subscapularis to the free edge of the prosthesis (Fig. 24). Subscapularis is therefore reattached in this position with through bone sutures. The rotator interval is closed. If there is any rotator cuff deficiency and this is repairable then full rotator cuff repair is made in the normal manner at this stage. Every attempt is made to close the rotator cuff complete

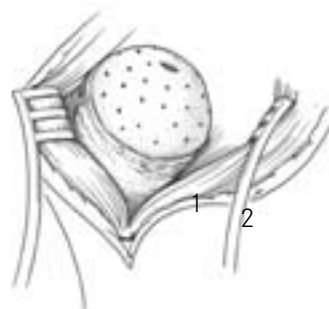


fig 23

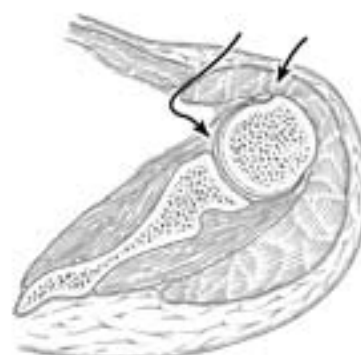

fig 24

Closure

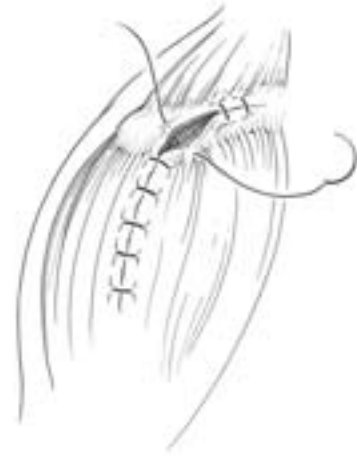Antero-superior Approach (Mackenzie)

The subscapularis is repaired using No.1 suture material (absorbable (PDS) or non-absorbable) without plicating the subscapularis or with through bone sutures. The rotator interval is closed. If there is any rotator cuff deficiency and this is repairable then full rotator cuff repair is made in the normal manner at this stage. Every attempt is made to close the rotator cuff completely.

The deltoid is reattached to the acromion with No. 1 absorbable sutures (PDS) through bone.

The deltoid split is approximated with 2/0 absorbable suture.

Subcutaneous fat is opposed with absorbable sutures and appropriate skin closure undertaken with Intra-dermal continuous absorbable suture (N01 Monocryl).

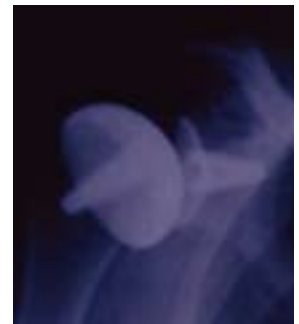

Deltopectoral Approach

The subscapularis is repaired using No.1 suture material (absorbable (PDS) or non-absorbable) without plicating the subscapularis or with through bone sutures. The rotator interval is closed. If there is any rotator cuff deficiency and this is repairable then full rotator cuff repair is made in the normal manner at this stage. Every attempt is made to close the rotator cuff completely.

The delto-pectoral interval is closed using 2 or 3 interrupted absorbable sutures.

Subcutaneous fat is opposed with absorbable sutures and appropriate skin closure undertaken with Intra-dermal continuous absorbable suture (W01 Monocryl).



Post-operative management

The patient is placed in a sling with bodybelt and brachial block analgesia used. Passive mobilising for the first 48 hours and passive assisted for five days. Active movements are then started as pain allows and the sling abandoned at three weeks. A stretching and strengthening programme is then advised standard for all shoulder replacements.


Instrumentation - Top Tray

No	Item	Description	Colour	Quantity
1	402600	Copeland Hum Drill Gde Sz 1	Brown	1
2	402601	Copeland Hum Drill Gde Sz 2	White	1
3	402602	Copeland Hum Drill Gde Sz 3	Black	1
4	402604	Copeland Hum Drill Gde Sz 4	Green	1
5	402606	Copeland Hum Drill Gde Sz 5	Blue	1
6	402620	Copeland Surface Cutter Sz 1	Brown	1
7	402621	Copeland Surface Cutter Sz 2	White	1
8	402622	Copeland Surface Cutter Sz 3	Black	1
9	402624	Copeland Surface Cutter Sz 4	Green	1
10	402626	Copeland Surface Cutter Sz 5	Blue	1
11	402630	Copeland Hum Provisional Sz 1	Brown	1
12	402631	Copeland Hum Provisional Sz 2	White	1
13	402632	Copeland Hum Provisional Sz 3	Black	1
14	402634	Copeland Hum Provisional Sz 4	Green	1
15	402626	Copeland Hum Provisional Sz 5	Blue	1
16	406514	Bio-Mod Hum Head Driver		1
17	402610	Copeland Spade Cutter Sz 1 to 2		1
18	402612	Copeland Spade Cutter Sz 3 to 8		1
19	402642	Copeland Surf Cutter Gde Sz 1 to 2		1
20	402644	Copeland Surf Cutter Gde Sz 3 to 8		1



Instrumentation - Bottom Tray

No	Item	Description	Colour	Quantity
21	402607	Copeland Hum Drill Gde Sz 6	Red	1
22	402609	Copeland Hum Drill Gde Sz 7	Brown	1
23	402608	Copeland Hum Drill Gde Sz 8	Grey	1
24	402627	Copeland Surface Cutter Sz 6	Red	1
25	402629	Copeland Surface Cutter Sz 7	Brown	1
26	402628	Copeland Surface Cutter Sz 8	Grey	1
27	402637	Copeland Hum Provisional Sz 6	Red	1
28	402639	Copeland Hum Provisional Sz 7	Brown	1
29	402638	Copeland Hum Provisional Sz 8	Grey	1
30	994500850	Bent Ring Retractor w/Ang Tip		1
31	30860	Ring Retractor Fukuda-Type Lg		1
32	402640	Copeland Hum Extractor Forceps		1



Implants



IMPLANTS

114310	Copeland Size 1 (small)
114302	Copeland Size 2
114311	Copeland Size 3 (standard)
114320	Copeland Size 4 (standard plus)
114312	Copeland Size 5 (large)
114306	Copeland Size 6
114307	Copeland Size 7
114317	Copeland Size 8 (extra large)
114313	Small Glenoid HA Coated
114314	Standard Glenoid HA Coated
114315	Standard Glenoid Extra Deep HA Coated
114318	Extra Large Glenoid HA Coated
114316	Standard Glenoid All Poly
NB	due to the increased diameter of the Extra Large Humeral component it MUST only be matched with the Extra Large Glenoid

X-RAY TEMPLATES

402323	105%
402324	110%
402325	115%

Cementless Surface Replacement Range

The Copeland prosthesis allows for its use as a hemiarthroplasty as well as a total shoulder replacement.

All of the cementless implants are coated with Hydroxyapatite (HA) on the bone contacting surfaces.

The cementless humeral HA Coated components are available in four sizes - standard, small, large and extra- large. The radius of curvature of the bearing surface is identical for all sizes, but the heights differ to cater for the range of anatomical sizes and offsets. The press-fit stem is tapered and fluted to provide maximum stability in the humerus. The components are manufactured from Cobalt-Chromium-Molybdenum Alloy. The cementless glenoid HA Coated components all have the same articulating surface curvature to match that of the humeral components. They are constructed from Cobalt-Chromium-Molybdenum Alloy, with a Polyethylene (ArCom™) bearing surface. Two sizes are available - standard and small; the standard glenoid component is also available with the option of all polyethylene for use in revision with cement.

Indications and Contraindications

90% of all patients presenting for possible shoulder replacement are suitable for surface replacement prosthesis. Only those with acute four-part fracture where a stem is needed as a scaffold to rebuild the fractured tuberosities around, or those with severe bone loss with no surface to replace and nonunions have to be considered for stemmed prosthesis.

The Copeland Shoulder has undoubted superiority over stemmed prostheses in young patients.

Indications

Pain and disability arising from the Gleno-humeral joint as a result of:
 Osteoarthritis.
 Rheumatoid arthritis and other inflammatory arthritis.
 Post-traumatic arthritis.
 Osteonecrosis.
 Gleno-humeral deformity with secondary arthritis.
 Rotator cuff tear arthropathy.
 Current practice is to use a hemiarthroplasty if the rotator cuff tendons are not reconstructible.

Contraindications

Active infection present in the region of the shoulder within the previous 2 years.
 Paralysis of the rotator cuff muscles or the deltoid muscle.
 Charcot disease of the shoulder.
 A past history of habitual instability is a relative contraindication.
 Absolute contraindications include:
 Infection and sepsis.

Relative contraindications include:

Osteoporosis.
 Metabolic disorders.
 Vascular insufficiency, muscular atrophy or neuromuscular disease.
 Unco-operative patient or patient unwilling or unable to follow instructions.
 Incompetent or deficient soft tissue surrounding the bone.
 Obesity.
 Foreign body sensitivity. Where material sensitivity is suspected, tests are to be made prior to implantation.

Instrumentation

The simple but comprehensive instrumentation is designed to prepare the humeral and glenoid articulating surfaces accurately for the insertion of the prosthetic components. Containing tapered drills and surface cutters for the humerus and glenoid, the set is completed by a range of provisional components to permit trial reduction, prior to implant insertion.

Pre Operative planning

Good quality AP and axial radiographs of the shoulder are essential.

In the severely damaged shoulder; particularly in rheumatoid arthritis, a CT scan will provide a detailed image of the bones - particularly the glenoid - and allow the surgeon to plan his operation and the need for bone grafting. Templates to estimate the prosthesis size needed are available, but the definite decision is made intraoperatively.

Surgical Technique

General considerations:

The prosthesis is suitable for insertion via either technique:

A. The standard anterior Deltpectoral approach.

B. The antero-superior (Mackenzie²) approach.

In Mr Copeland's opinion the advantages of the antero-superior technique are:

Smaller and neater scar.

Quicker post-operative recovery.

Easier access via rotator interval.

Easier access to the glenoid "en face".

Better access to reconstruct the posterior and superior rotator cuff;

Easy access to do acromioplasty and excision arthroplasty of the AC joint if this is also indicated.

If the rotator cuff is intact or a repairable rotator cuff defect is seen then an anterior acromioplasty is made with partial resection of the coracoacromial ligament. The coracoacromial arch is left undisturbed if there is complete loss of rotator cuff. If pre-operative x-rays have indicated arthritic change at the acromioclavicular joint and symptoms suggest this is a site of pain, then an excision arthroplasty can be done at this stage and improves exposure.

Cleaning Instructions

1. Copeland Shoulder Guide wires

- Ensure wires are sharp, and are straight and can pass easily down the cannulated instruments

2. Alignment pin guides

- Ensure that the cannulae are clear of any debris and the guide wire can run smoothly through the instrument



3. Cannulated Reamers

- Ensure that the cannulae are clear of any debris and the guide wire can run smoothly through the instrument
- Ensure that cutting teeth are aligned, sharp and are clear of any debris



4. Humeral Spade Cutters

- Ensure that the cannulae are clear of any debris and the guide wire can run smoothly through the instrument
- Ensure that there is no debris on the cutting edge of the spade and that the edges are sharp.



5. Humeral Peg Provisionals

- Ensure that the wire is straight and that the coloured rings are free of any debris



6. Humeral Trials

- Ensure that no debris adheres to the inner surface and holes in the provisional prosthesis
- Ensure that the edges of the holes in the outer surface are not damaged



7. Humeral Provisional Grasper

- Ensure that the arms of the grasper can move in a scissor-like fashion.



Copeland



Biomet UK Ltd
Waterton Industrial Estate
Bridgend, South Wales
CF31 3XA, United Kingdom
Tel. +44 (0)1656 655221
Fax. +44 (0)1656 645454

Copeland

BIOMET
■■■■■■■ Europe