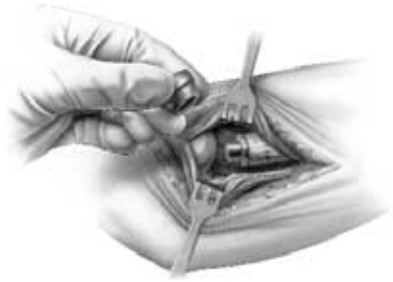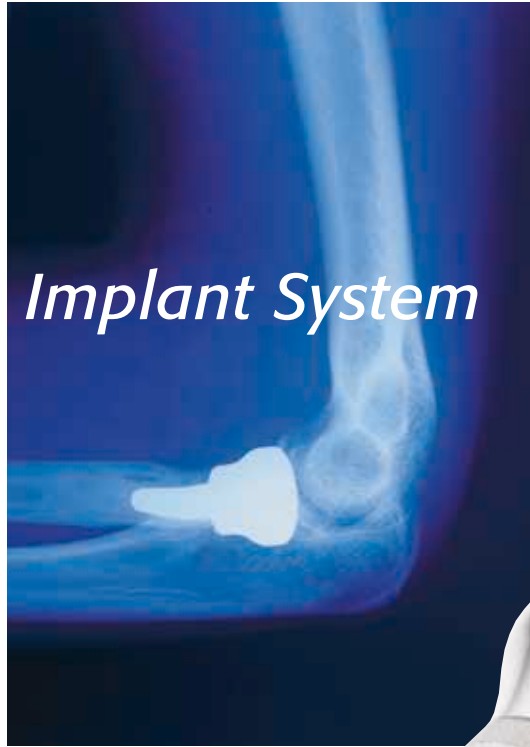


# *Surgical Technique*

## *rHead™ Radial Implant System*



A V A N T A

# *rHead™ Radial Implant System*

## SURGICAL TECHNIQUE

### *Contents*

---

INTRODUCTION	1
Surgeon Preferences	2
Anatomy of the Radial Head	3
Disorders of the Proximal Radioulnar Joint	4
Design Rationale	5
SURGICAL TECHNIQUE	
Step 1. The Initial Incision	6
2. Capsular Exposure	7
3. Using the Radial Head Resection Guide	8
4. Resecting the Radial Head	9
5. Intramedullary Preparation	10
6. Trial Reduction	11
7. Implanting the Final Components	12
8. Closure	13
9. Aftercare	13
INDICATIONS, WARNINGS, PRECAUTIONS	Back Cover

The rHead™ Radial Implant System was developed in cooperation with the Mayo Clinic, Rochester, MN.

Proper surgical procedures and techniques are necessarily the responsibility of the medical professional. Each surgeon must evaluate the appropriateness of the surgical technique used based on personal medical training and experience.

The contents of this document are protected from unauthorized reproduction or duplication under U.S. federal law. Permission to reproduce this document (for educational/instructional use only) may be obtained by contacting Avanta Orthopaedics.

## ***Introduction***

---

The radial head is an important component of both normal elbow as well as forearm function contributing to the radiocapitellar and proximal radioulnar joints. Stability testing has demonstrated that the radial head is an important "second line" constraint to resist valgus loads (after the medial collateral ligament).

Radial head resection, while occasionally necessary from fracture, osteochondrosis, or secondary arthritis, is not without adverse effect on both elbow and forearm function. In-depth laboratory studies have demonstrated the important role of the radial head in elbow kinematics, force distribution, and load transfer across the forearm and elbow joint.

Radial head resection has been implicated in persistent elbow instability in elbow fracture-dislocation, rotational instability injuries, and medial-lateral translation injury. Forearm axial instability can result from radial head excision if the remaining stabilizers have been compromised (the Essex-Lopresti lesion). The common thread in all of the instabilities of the forearm and elbow is one of ligament injury in association with bone loss. Once the secondary stabilizer is removed (i.e. radial head) and elements of the soft tissues (collateral ligaments, interosseous membrane of the forearm and/or distal and proximal radio-ulnar joints) are compromised, joint instability is noted to increase.

Replacement of the radial head is an anatomic and functional solution to persistent elbow and forearm instability when internal fixation of the radial head fractures cannot be performed.



## ***Surgeon Preferences***

---

Recommended clinical situations for potential use of this device are as follows:

### Acute Trauma

1. Comminuted radial head fracture requiring resection associated with ligament injury
  - a) Elbow dislocation
  - b) Distal radioulnar joint injury (Essex-Lopresti injury)
2. Comminuted radial head fracture requiring resection with associated fracture(s)
  - a) Coronoid type II or III fracture (single or comminuted more than half of the coronoid process)
  - b) Olecranon type III fracture (displaced or comminuted and unstable)
3. After radial head excision with evidence of medial collateral ligament insufficiency.

### Reconstruction

1. Failed previous radial head resection with elbow or forearm instability
2. Failed silicone radial head replacement
3. With interposition arthroplasty if radial head excised and residual elbow instability exists
4. Stabilization of the forearm and elbow after an Essex-Lopresti injury
5. Complex elbow instability with reconstruction of the medial or lateral ulnohumeral collateral ligaments.

Clinical situations where the use of this device should be avoided:

### Acute Trauma

1. Older patient with a comminuted radial head fracture requiring radial head excision without evidence of elbow instability or other associated injury (greater than age 65)
2. Open fracture of the radial head, olecranon or associated elbow isolation with high risk for sepsis
3. Mason type I or II radial head fractures
4. Mason type II radial head fracture not associated with elbow or forearm instability.

### Reconstruction

1. Malalignment of the forearm or proximal radius with the capitellum
2. Proximal radial shaft fractures associated with comminuted radial head fracture
3. Disease or injury of the capitellum (e.g. Osteochondrosis of the capitellum).

### General

1. Prior sepsis or concern regarding wound contamination
2. Known allergy to metallic constituents
3. Skeletal immaturity
4. Bone, tendon or muscle, or adjacent soft tissue compromised by disease, trauma or prior implantation which cannot provide adequate elbow stability or fixation for the prosthesis.

## ***Anatomy of the Radial Head***

1. The radial head articulates with the capitellum and radial (greater sigmoid) notch of the ulna (FIGURE A).
2. The radial head makes a 15° lateral angle to the radial shaft away from the tuberosity (FIGURE B).
3. Ligaments about the radial head provide important soft tissue support and are essential to elbow stability after radial head replacement (FIGURE C).
4. Stress distribution varies in pronation and supination but averages 60% radiohumeral and 40% at the ulnohumeral articulation.
5. Elbow stability is related to articular geometry and ligament constraint.
6. Loss of medial collateral ligament and/or radial head produces primary or secondary elbow instability. Radial head replacement aids in restoring elbow stability (FIGURE D).

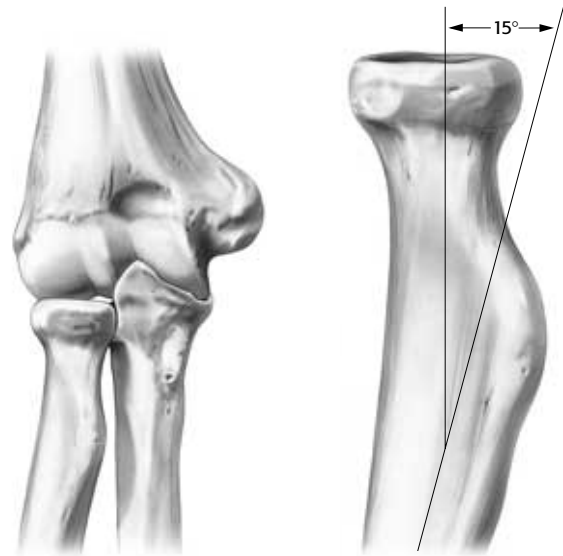


FIGURE A

FIGURE B

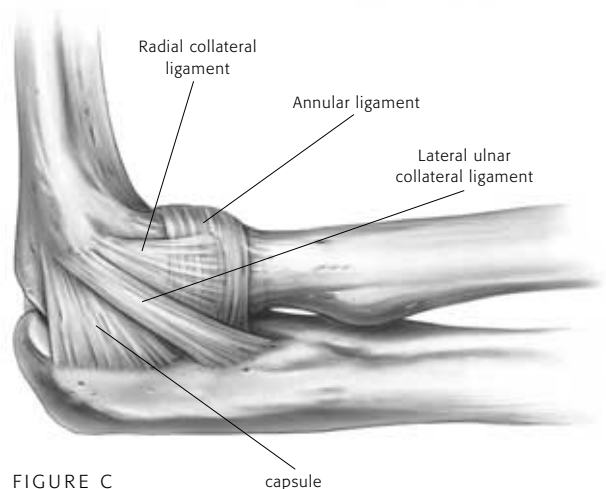


FIGURE C

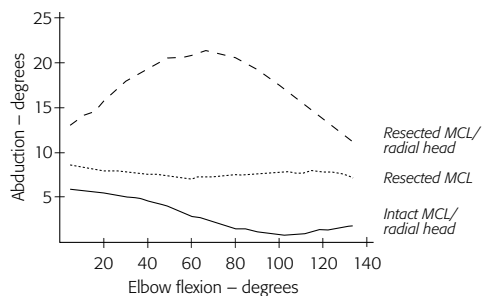


FIGURE D

## ***Disorders of the Proximal Radioulnar Joint***

---

The proximal radioulnar and radiocapitellar joint articulations may be affected by traumatic and acquired disorders. Traumatic injury is common. Injuries include:

1. Radial head fractures (Mason types I-III) and Mason Type IV – complex radial head fracture associated with ligament injuries
2. Combined proximal ulna fracture with radial head dislocation or fracture (Monteggia lesions I-IV)
3. Radial head fracture associated with dislocation of the elbow (anterior, posterior or lateral)
4. Forearm and elbow injuries (radial head fracture and interosseous membrane disruption) – The Essex-Lopresti lesion.

### ***Elbow Instability***

All but one of these above conditions relate to elbow instability and are classified as:

1. Dislocation of the elbow with radial head fracture
2. Monteggia variant with olecranon and radial head fracture
3. Concurrent medial collateral ligament disruption
4. Fracture of a major portion of the coronoid.

### ***Treatment***

Comminuted radial head fractures Type III (FIGURE E) associated with medial collateral ligament injury require stabilization by medial collateral ligament repair and internal fixation of the radial head or radial head replacement. Excision of comminuted fracture of the radial head requires radial head replacement if elbow instability is present.

Radial head fracture with dislocation or Type III coronoid fractures also require treatment based on the type of radial head replacement.

### ***Essex-Lopresti Injury***

Forearm disassociation (Essex-Lopresti injury) requires careful diagnosis and initial or delayed radial head stabilization.

The following should be considered:

1. History of axial loading forearm injury
2. Radial head fracture (often comminuted)
3. Tenderness and pain over DRUJ and forearm.

Treatment:

1. Stabilization of the radial head
  - a) Open reduction & internal fixation
  - b) Radial head prosthesis
2. Immobilization of forearm
3. Operative repair of TFCC
4. Repair or late reconstruction of interosseous membrane.

Radial head replacement is indicated to restore elbow and forearm stability in these conditions.

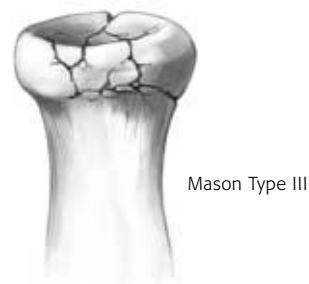

FIGURE E

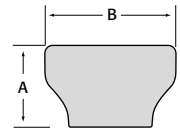
## Design Rationale

The Avanta radial head implant is an anatomic design. It duplicates in three sizes the anthropomorphic differences of radial head size. The concave articular surface of the radial head component is designed to anatomically articulate with the convexity of the capitellum for an anatomic joint surface contact area. The circumference matches the normal proximal radioulnar joint articulation, preserves the annular ligament and minimizes release for exposure of the important lateral ulnar collateral ligament.

A Morse taper fit allows for radial head placement onto the radial stem. The radial stem design has a length that, in most circumstances, will extend to but not past the radial tuberosity. The stem is implanted first, followed by head placement. With appropriate sized broaches, the stem insertion should be uncomplicated. Correct anatomic position of the forearm is necessary with the center of the forearm rotation aligned between the radial head and distal ulnar styloid. Rotational malalignment will cause poor radio-capitellar joint contact and potential for radial head subluxation. A radial head resection guide assists in both radial neck osteotomy and radial stem alignment. Note that the anatomy of the proximal radial head and neck are offset 15° laterally to the shaft of the radius with the forearm in supination (SEE FIGURE B, PAGE 3).

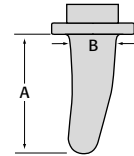
### Radial Head Component

SIZE	CAT NO	DIMENSIONS (mm)	
		A	B
2	RHA-H2	9.0	18.0
3	RHA-H3	12.0	21.0
4	RHA-H4	15.0	24.0



### Standard Stem

SIZE	CAT NO	DIMENSIONS (mm)	
		A	B
2	RHA-S2	18.0	7.2
3	RHA-S3	20.0	8.0
4	RHA-S4	22.0	8.8



# SURGICAL TECHNIQUE

## *The Initial Incision*

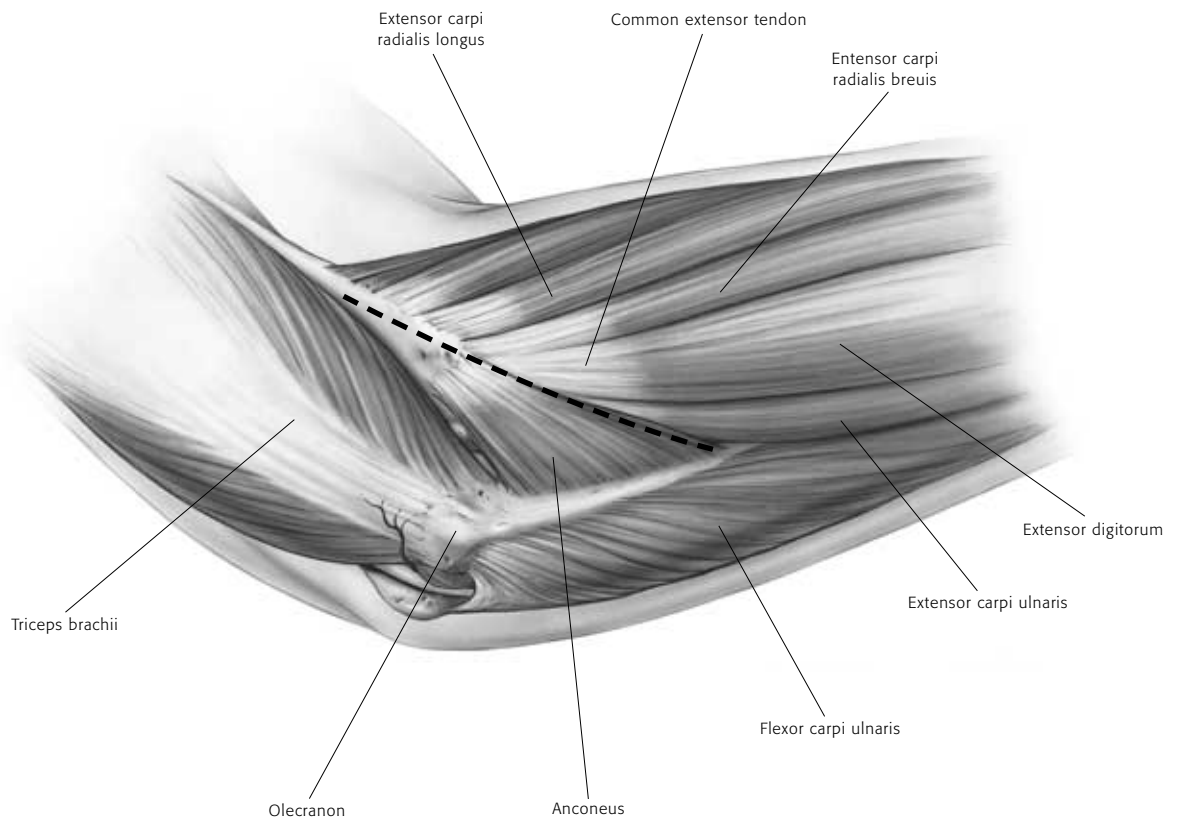
---

1

The patient is placed under a general or a regional anesthesia. The extremity is prepped and draped in the usual sterile fashion. A sterile tourniquet is often a good option. An arm table may be used if the patient is in a supine position or the arm may be brought across the chest.

A classic Kocher skin incision is made identifying the interval between the anconeus and the extensor carpi ulnaris (FIGURE 1). The incision extends approximately 6-7cm. The dissection is carried down to the joint capsule. The origin of the anconeus can be released subperiosteally and retracted posteriorly to permit adequate exposure of the capsule.

FIGURE 1



## Capsular Exposure

2

If the elbow is stable, the capsule is exposed by elevating a portion of the extensor carpi ulnaris sufficiently to allow identification of the lateral collateral ligament complex (FIGURE 2A). Alternatively, the extensor carpi ulnaris may be split longitudinally in line with its fibers staying anterior to the attachment of the lateral collateral ligament. The lateral capsule is divided slightly anteriorly to the collateral ligament and the annular ligament and capsule are reflected anteriorly and posteriorly to expose the radial head.

A portion of the lateral collateral ligament and anterior capsule can be reflected off the lateral epicondyle and anterior humerus to expose the capitellum if necessary. The lateral ulnohumeral ligament must not be disturbed. If the ligament has been disrupted, then the exposure progresses through the site of disruption to expose the radiohumeral joint. The common extensor tendon and elbow joint capsule are retracted as needed to maximize exposure (FIGURE 2B).

FIGURE 2A

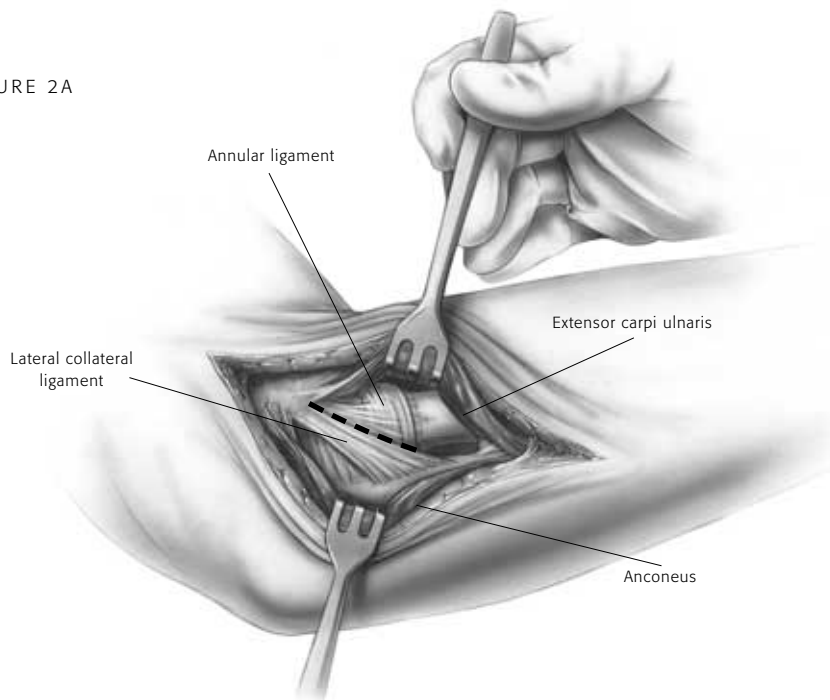
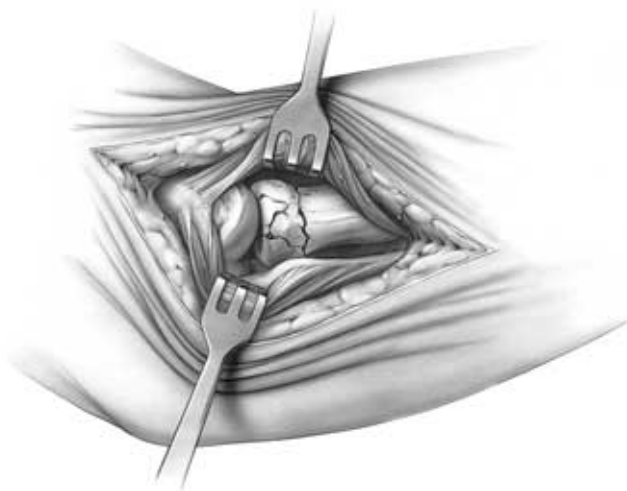


FIGURE 2B



## Using the Radial Head Resection Guide

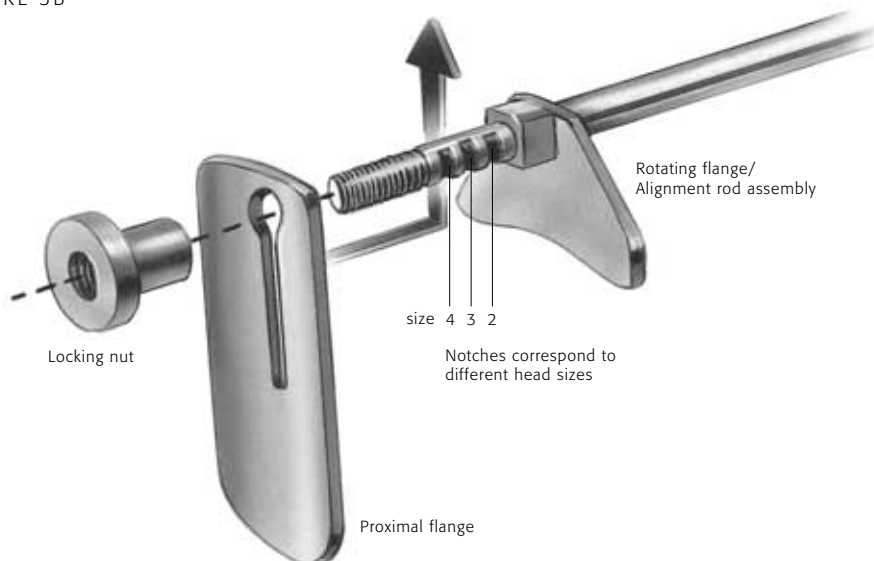
3 The radial neck cut requires a resection guide. The device is inserted over the capitellum with the axis of the alignment rod oriented over the ulnar styloid (FIGURE 3A). This alignment reflects the anatomic axis of forearm rotation. Test forearm rotation with the guide in place to ensure proper alignment. The proximal flange of the guide is placed against the articular surface of the capitellum and the rotating flange/alignment rod assembly is then guided proximally or distally to the desired length of radial

head resection (FIGURE 3B). Each notch on the threaded portion of the rod corresponds to a different head size. When the radial head has been previously resected, the rotating flange placement direction must be matched to the anticipated radial head implant size and the axis of forearm rotation. Once the desired length has been established, the proximal flange is secured by tightening the locking nut. The guide must be again aligned to the ulnar styloid (the axis of forearm rotation), not the radial shaft.

FIGURE 3A



FIGURE 3B



## Resecting the Radial Head

4

The blade should be guided by the distal surface of the flange (FIGURE 4A). During the resection, the forearm is pronated and supinated while the cutting guide is used to align the sawblade perpendicular to the axis of rotation (FIGURE 4B). Once initial alignment cuts have been made, the guide is removed and the resection is completed. The distal extent of resection is the minimal amount that is consistent

with the restoration of function as dictated by the fracture line or previous radial head resection (FIGURE 4C). This includes at least the margin articulating with the ulna at the radial notch.

In addition, radial length must be restored by a lamina spreader (axial traction) if there is a positive ulnar variance.

FIGURE 4A

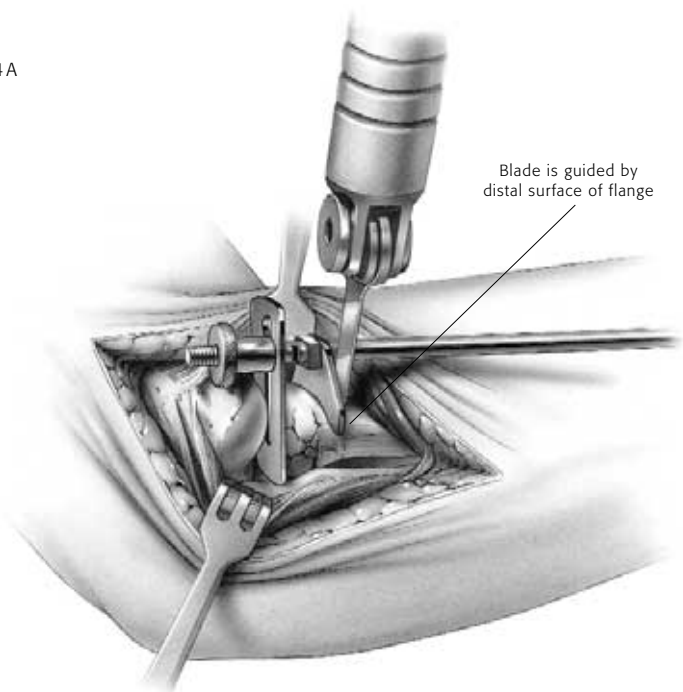
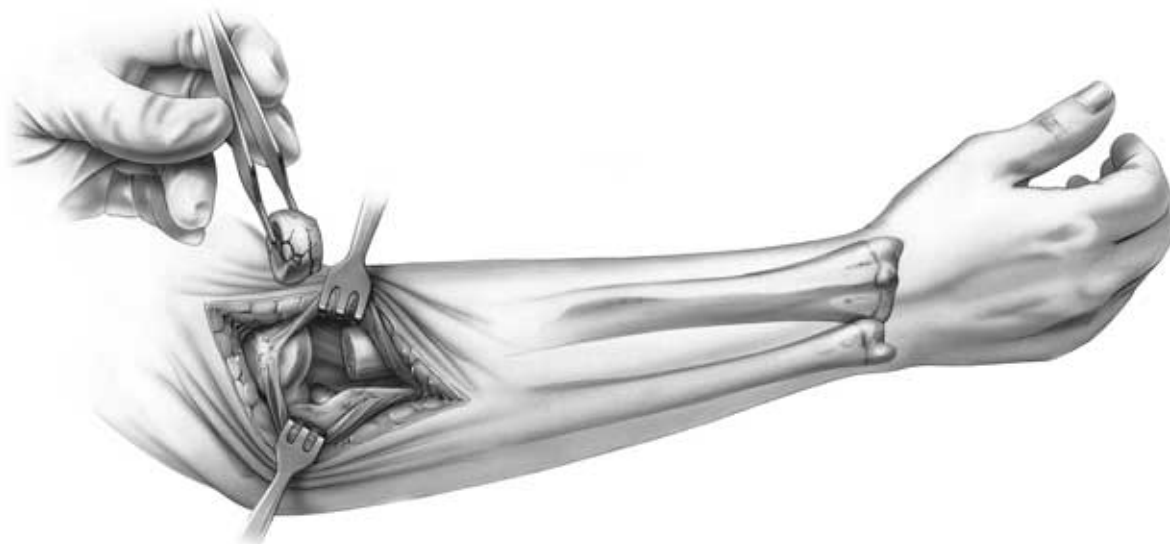


FIGURE 4B



FIGURE 4C



## ***Intramedullary Preparation***

---

5

If the elbow is unstable, varus stress and rotation of the forearm into supination allows improved access to the medullary canal. If the elbow is stable but the exposure is not adequate to access the medullary canal, careful reflection of the origin of the collateral ligament from the lateral epicondyle may be necessary to permit subluxation to the medullary canal. The canal is entered with a starter awl using a twisting motion (FIGURE 5A). The canal is then broached taking care

to identify the proper axial orientation (FIGURE 5B). The forearm should be in mid-rotation with the tuberosity directed medially. This position is favorable for broaching and implantation as the curve of the broach/implant will point lateral or away from the radial tuberosity (SEE FIGURE 6A, PAGE 11). Serial sized broaches are used until the broach fits snugly in the canal at the appropriate depth.

FIGURE 5A

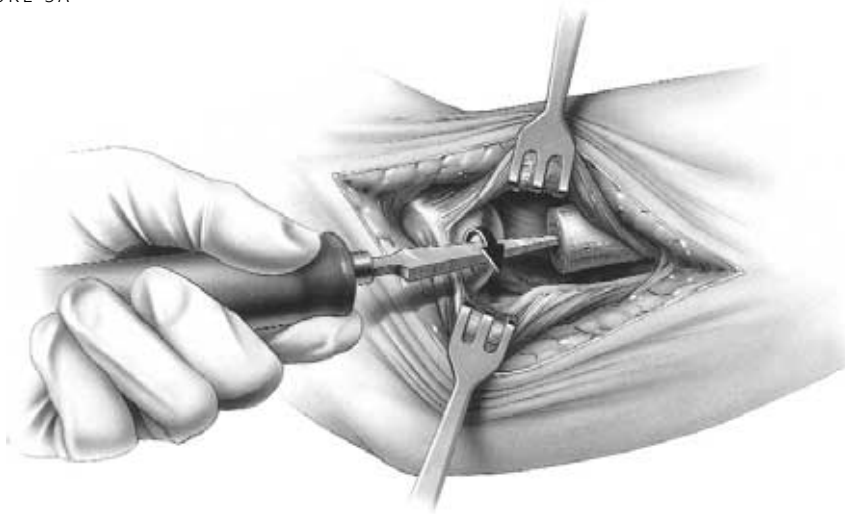
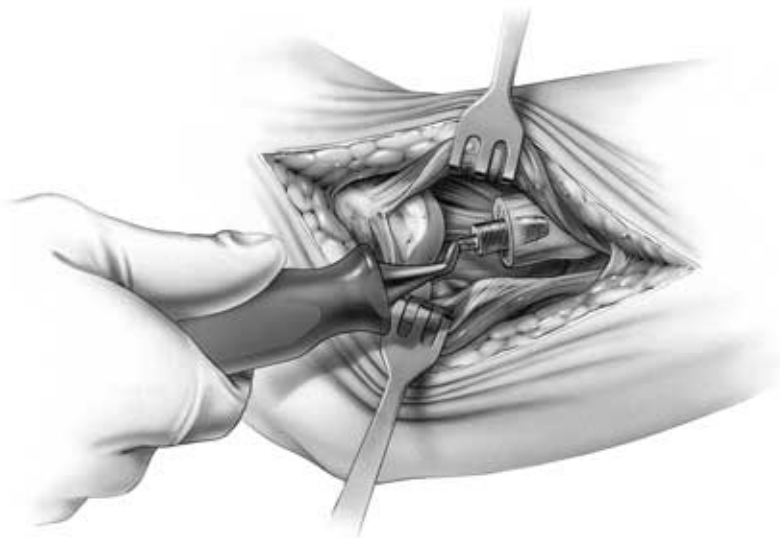


FIGURE 5B



## *Trial Reduction*

---

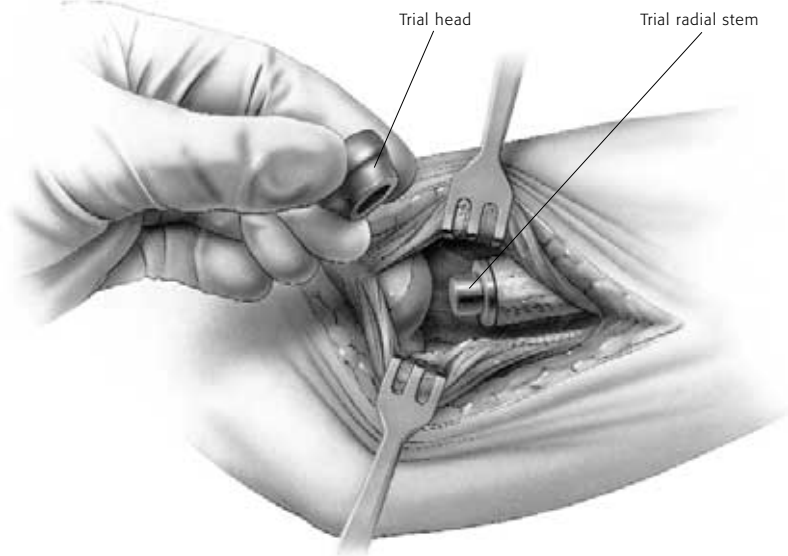
6 The appropriate sized trial stem is inserted in an arc-like fashion, facilitated by the curve of the stem. (FIGURE 6A). Assure the collar is flush with the resected head. The trial head is secured to the stem (FIGURE 6B), and tracking, both in flexion

and extension and forearm rotation, should be carefully assessed. Malalignment of the osteotomy will cause abnormal tracking during flexion/extension and forearm pronation/supination.

FIGURE 6A



FIGURE 6B



## Implanting the Final Components

7

Once acceptable alignment has been determined, the trials are removed and the permanent prosthesis is inserted in two steps. First, using the same arc-like motion as shown in FIGURE 6A, the radial stem is placed in the medullary canal and tapped into place with the impactor (FIGURE 7A). If a firm fixation is not present at the time of the insertion of the trial stem (i.e. stem can be easily extracted from or rotated in the medullary canal), then bone cement (PMMA) is recommended. Second, the modular head is placed

over the taper while applying longitudinal distraction and/or varus stress to distract the radiocapitellar interface sufficiently to permit the radial head to be inserted. Once inserted over the taper, the radial head is secured using the impactor (FIGURE 7B). The elbow is then reduced (FIGURE 7C) and tested again in flexion/extension and pronation/supination.

**NOTE** Care should be taken to protect the taper from any damage, including but not limited to scratches and contact with bone cement.

FIGURE 7A

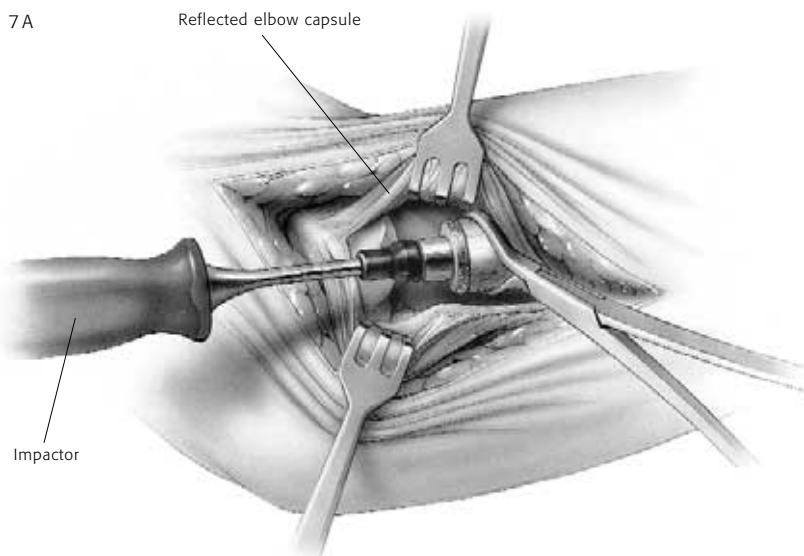


FIGURE 7B

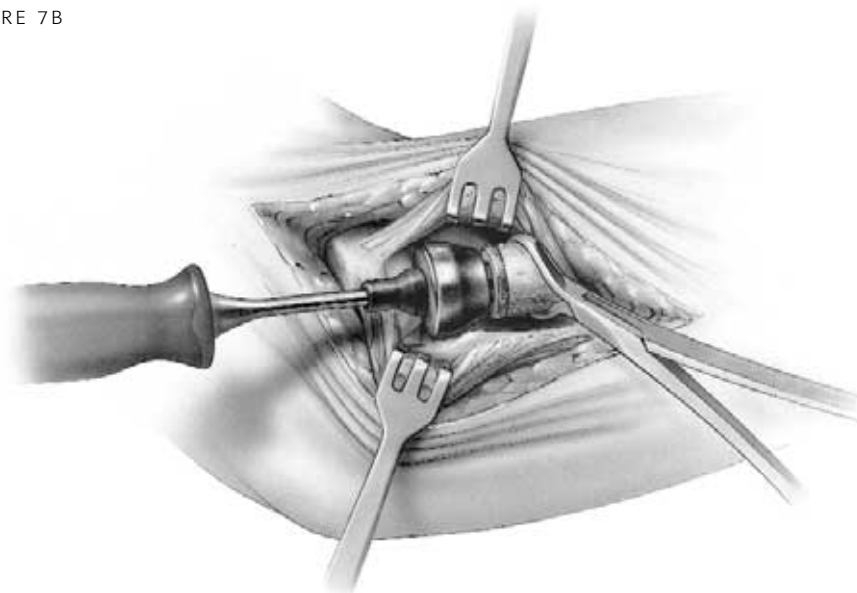
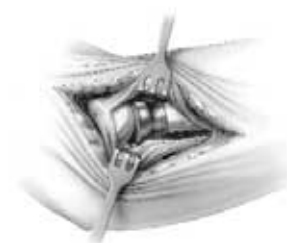


FIGURE 7C



## Closure

---

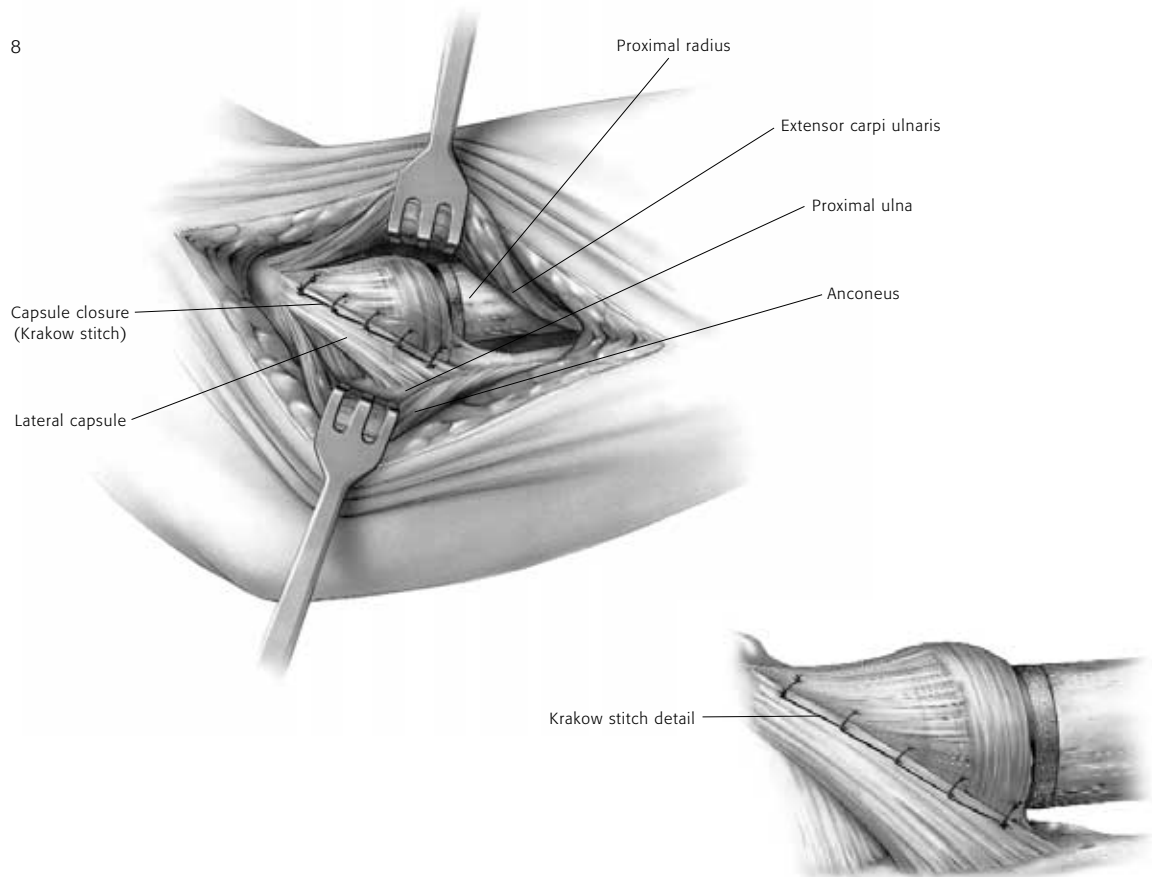
8

A simple closure is permitted if the collateral ligament is not disrupted.

If the collateral ligament has been disrupted, a Krakow stitch is used in the absence of the lateral ulnar collateral ligament. A No. 5 absorbable suture is placed distally, crossing the site of the lateral ulnar collateral ligament and is then brought proximally.

Both ends of the suture are brought through a drill hole at the anatomic origin of the lateral collateral ligament complex and exit posteriorly. The forearm is placed in full or partial pronation and the suture tied (FIGURE 8). The elbow is splinted at 90 degrees flexion and in neutral to full pronation.

FIGURE 8



## Aftercare

---

9

Passive flexion and extension is allowed on the second day assuming the elbow is considered stable. The goal of radial head replacement and soft tissue repair is to achieve elbow stability. Both flexion/extension and pronation/supination arcs are allowed

without restriction. Active motion can begin by day five.

As with any prosthetic replacement, long term aftercare requires surveillance. If the implant is asymptomatic and tracks well, routine removal is not necessary.

## ***Indications for Use***

---

Avanta Orthopaedics Radial Head implant is intended for replacement of the proximal end of the radius:

- Primary replacement after complex (comminuted) fracture of the radial head
- Symptomatic sequelae after radial resection
- Axial forearm instability
- Failed silicone radial head implant
- Elbow instability associated with radial head fracture or excision of radial head
- Replacement of the radial head for degenerative, or post-traumatic disabilities presenting pain, crepitation and decreased motion at the radiohumeral and/or proximal radio-ulnar joint.

## ***Contraindications***

---

- Bone musculature, tendons, or adjacent soft tissue compromised by disease, infection, or prior implantation which cannot provide adequate support or fixation for the prosthesis
- Any active or suspected infection in or around the joint
- Skeletal immaturity
- Physiologically or psychologically unsuitable patient
- Known sensitivity to materials used in this device
- Possibility for conservative treatment

## ***Warnings***

---

*(See also the Patient Counseling Information Section)*

- Strenuous loading, excessive mobility, and articular instability all may lead to accelerated wear and eventual failure by loosening, fracture, or dislocation of the device. Patients should be made aware of the increased potential for device failure if excessive demands are made upon it.
- Notification in accordance with the California Safe Drinking Water and Toxic Enforcement Act of 1986 (Proposition 65): This product contains a chemical(s) known to the State of California to cause cancer, and/or birth defects and other reproductive toxicity.

## ***Precautions***

---

- The implant is provided sterile in an undamaged package. If either the implant or the package appears damaged, expiration date has been exceeded, or if sterility is questioned for any reason, the implant should not be used. Do not resterilize.
- Meticulous preparation of the implant site and selection of the proper size implant increases the potential for a successful outcome.
- The implant should be removed from its sterile package only after the implant site has been prepared and properly sized.
- Implants should be handled with blunt instruments to avoid scratching, cutting or nicking the device so as not to adversely affect the implant performance. Polished bearing and taper surfaces must not come in contact with hard or abrasive surfaces.
- The head and stem should not be implanted if the tapers are possibly damaged, this includes repeated attaching and detaching.
- The head of the prosthesis is impacted on to the head of the stem. Prior to assembly confirm that the tapers are dry and free from contaminant.

## ***Patient Counseling Information***

---

*(See also Warnings)*

In addition to the patient related information contained in the Warnings and Adverse Events sections, the following information should be conveyed to the patient.

- While the expected life of total joint replacement components is difficult to estimate, it is finite. These components are made of foreign materials which are placed within the body for the potential restoration of mobility or reduction of pain. However, due to the many biological, mechanical and physiochemical factors which affect these devices, the components cannot be expected to withstand the activity level and loads of normal healthy bone for an unlimited period of time.
- Adverse effects may necessitate reoperation, revision, or fusion of the involved joint.

Please refer to implant package insert for additional product information including precautions and warnings.

## ***Surgical Video***

---

For a surgical video of this product contact Avanta Orthopaedics.

**A V A N T A**  
**ORTHOPAEDICS**

9369A Carroll Park Drive, San Diego, CA 92121 858-452-8580 / 800-778-8837 / fax 858-452-9945

www.avanta.org © 2000 Avanta Orthopaedics 19-0377 rev.A

CE  
0123