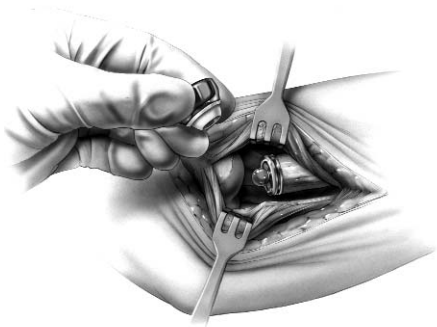
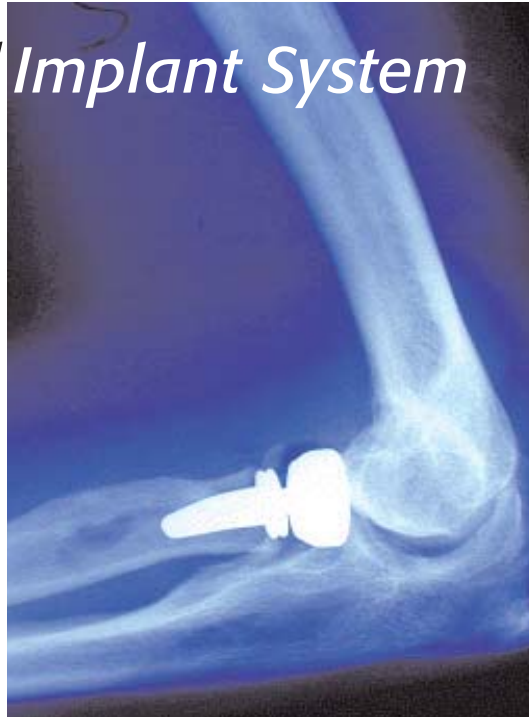

Surgical Technique

rHead™ Radial Implant System *Recon*



A V A N T A

rHeadTM Recon Radial Implant System

SURGICAL TECHNIQUE

Contents

INTRODUCTION	1
Surgeon Preferences	2
Anatomy of the Radial Head	3
Disorders of the Proximal Radioulnar Joint	4
Design Rationale	5
 SURGICAL TECHNIQUE	
Step 1. The Initial Incision	6
2. Capsular Exposure	7
3. Using the Radial Head Resection Guide	8
4. Resecting the Radial Head	9
5. Intramedullary Preparation	10
6. Trial Stem Insertion	11
7. Trial Head Insertion	11
8. Implanting the Final Components	12
9. Closure	13
10. Aftercare	13
 INDICATIONS, WARNINGS, PRECAUTIONS	Back Cover

The rHead^{RECON}TM Radial Implant System was developed in cooperation with the Mayo Clinic, Rochester, MN.

Proper surgical procedures and techniques are necessarily the responsibility of the medical professional. Each surgeon must evaluate the appropriateness of the surgical technique used based on personal medical training and experience.

The contents of this document are protected from unauthorized reproduction or duplication under U.S. federal law. Permission to reproduce this document (for educational/instructional use only) may be obtained by contacting Avanta Orthopaedics.

Introduction

The radial head is an important component of both normal elbow as well as forearm function contributing to the radiocapitellar and proximal radioulnar joints. Stability testing has demonstrated that the radial head is an important "second line" constraint to resist valgus loads (after the medial collateral ligament).

Radial head resection, while occasionally necessary from fracture, osteochondrosis, or secondary arthritis, is not without adverse effect on both elbow and forearm function. In-depth laboratory studies have demonstrated the important role of the radial head in elbow kinematics, force distribution, and load transfer across the forearm and elbow joint.

Radial head resection has been implicated in persistent elbow instability in elbow fracture-dislocation, rotational instability injuries, and medial-lateral translation injury. Forearm axial instability can result from radial head excision if the remaining stabilizers have been compromised (the Essex-Lopresti lesion). The common thread in all of the instabilities of the forearm and elbow is one of ligament injury in association with bone loss. Once the secondary stabilizer is removed (i.e. radial head) and elements of the soft tissues (collateral ligaments, interosseous membrane of the forearm and/or distal and proximal radio-ulnar joints) are compromised, joint instability is noted to increase.

Replacement of the radial head is an anatomic and functional solution to acute elbow and forearm instability when internal fixation of the radial head fractures cannot be performed. It is also indicated in instances in which residual symptoms of pain or instability prompt the use of the delayed insertion of a radial head implant as a reconstruction procedure.



Surgeon Preferences

In general the rHead_{RECON}TM was designed for use in circumstances in which the proximal radius cannot be anatomically aligned with the capitellum.

Recommended clinical situations for potential use of the rHead_{RECON}TM are as follows:

Acute Trauma

1. Comminuted radial head fracture requiring resection associated with ligament injury
 - a) Elbow dislocation
 - b) Distal radioulnar joint injury (Essex-Lopresti injury)
2. Comminuted radial head fracture requiring resection with associated fracture(s)
 - a) Coronoid type II or III fracture (single or comminuted more than half of the coronoid process)
 - b) Olecranon type III fracture (displaced or comminuted and unstable)
3. After radial head excision with evidence of medial collateral ligament insufficiency.

Reconstruction

Malalignment of the resected proximal radius under the following circumstances:

1. Instability after radial head resection in the context of:
 - a) medial collateral deficiency or reconstruction
 - b) lateral collateral deficiency or reconstruction
 - c) axial (Essex-Lopresti) stabilization
2. Failed prior radial head replacement.
3. With interposition arthroplasty if the radial head is excised and residual elbow instability is enhanced by replacement.

Clinical situations where the use of this device should be avoided:

Acute Trauma

1. Older patient with a comminuted radial head fracture requiring radial head excision without evidence of elbow instability or other associated injury (greater than age 65)
2. Open fracture of the radial head, olecranon or associated elbow dislocation with high risk for sepsis
3. Mason type I or II radial head fractures
4. Mason type II radial head fracture not associated with elbow or forearm instability.

Reconstruction

1. Severe malalignment of forearm, proximal radius or ulna (e.g. congenital radial head dislocation or malunion Monteggia fracture).
2. Lack of proper alignment with trial insertion.
3. Disease or injury of the capitellum (e.g. Osteochondrosis of the capitellum).

General

1. Prior sepsis or concern regarding wound contamination
2. Known allergy to implant constituents
3. Skeletal immaturity
4. Bone, tendon or muscle, or adjacent soft tissue compromised by disease, trauma or prior implantation which cannot provide adequate elbow stability or fixation for the prosthesis.

Anatomy of the Radial Head

1. The radial head articulates with the capitellum and radial (greater sigmoid) notch of the ulna (FIGURE A).
2. The radial head makes a 15° lateral angle to the radial shaft away from the tuberosity (FIGURE B).
3. Ligaments about the radial head provide important soft tissue support and are essential to elbow stability after radial head replacement (FIGURE C).
4. Stress distribution varies in pronation and supination but averages 60% radiohumeral and 40% at the ulnohumeral articulation.
5. Elbow stability is related to articular geometry and ligament constraint.
6. Loss of medial collateral ligament and/or radial head produces primary or secondary elbow instability. Radial head replacement aids in restoring elbow stability (FIGURE D).
7. After radial head resection, or following ulnar fracture, the proximal radius may not align with the capitellum.

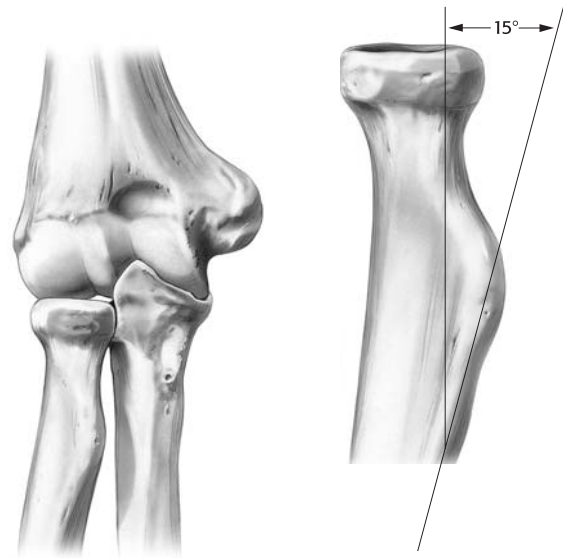


FIGURE A

FIGURE B

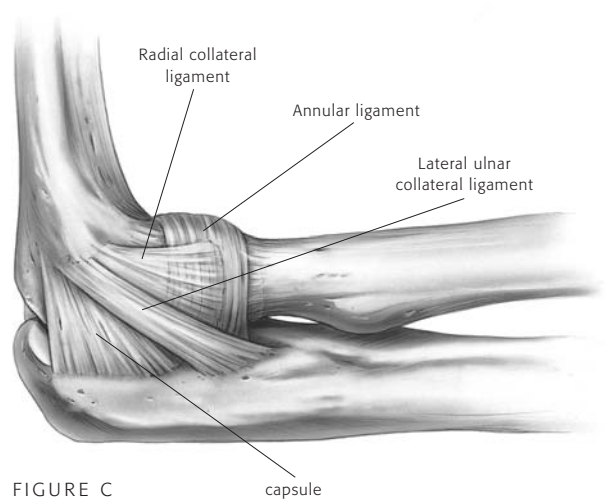


FIGURE C

capsule

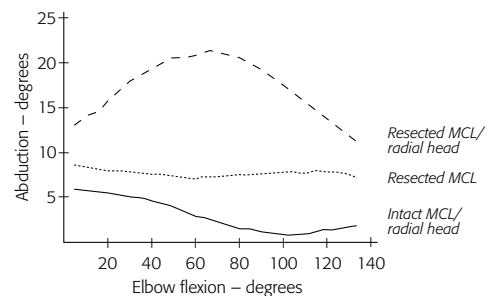


FIGURE D

Disorders of the Proximal Radioulnar Joint

The proximal radioulnar and radiocapitellar joint articulations may be affected by traumatic and acquired disorders. Traumatic injury is common. Injuries include:

1. Radial head fractures (Mason types I-III) and Mason Type IV – complex radial head fracture associated with ligament injuries (FIGURE E)
2. Combined proximal ulna fracture with radial head dislocation or fracture (Monteggia lesions I-IV)
3. Radial head fracture associated with dislocation of the elbow (anterior, posterior or lateral)
4. Forearm and elbow injuries (radial head fracture and interosseous membrane disruption) – The Essex-Lopresti lesion.

Elbow Instability

All but one of these above conditions relate to elbow instability and are classified as:

1. Dislocation of the elbow with radial head fracture
2. Monteggia variant with olecranon and radial head fracture
3. Concurrent medial collateral ligament disruption
4. Fracture of a major portion of the coronoid.

Delayed Treatment

If the injury was not successfully treated initially, a delayed reconstruction of the radio-humeral joint is sometimes required. This is especially true in instances of residual angular or axial instability.

Essex-Lopresti Injury

Forearm disassociation (Essex-Lopresti injury) requires careful diagnosis and initial or delayed radial head stabilization.

The following should be considered:

1. History of axial loading forearm injury
2. Radial head fracture (often comminuted)
3. Tenderness and pain over DRUJ and forearm.

Treatment:

1. Stabilization of the radial head
 - a) Open reduction & internal fixation
 - b) Radial head prosthesis
2. Immobilization of forearm
3. Operative repair of TFCC
4. Repair or late reconstruction of interosseous membrane.

Radial head replacement is indicated to restore elbow and forearm stability in these conditions.

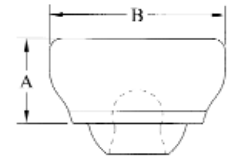
Design Rationale

The Avanta rHead_{RECON}[™] implant is an anatomic design with an element of alignment flexibility. It duplicates in multiple sizes the anthropomorphic differences of radial head size. The concave articular surface of the radial head component is designed to anatomically articulate with the convexity of the capitellum for an anatomic joint surface contact area. The circumference matches the normal proximal radioulnar joint articulation, preserves the annular ligament and minimizes release for exposure of the important lateral ulnar collateral ligament.

The radial stem design has a length that, in most circumstances, will extend to but not past the radial tuberosity. The stem is implanted first, followed by head placement. With appropriate sized broaches, the stem insertion should be uncomplicated. Correct anatomic position of the forearm is necessary with the center of the forearm rotation aligned between the radial head and distal ulnar styloid. Rotational malalignment will cause poor radio-capitellar joint contact and potential for radial head subluxation. A radial head resection guide assists in both radial neck osteotomy and radial stem alignment. Note that the anatomy of the proximal radial head and neck are offset 15° laterally to the shaft of the radius with the forearm in supination (SEE FIGURE B, PAGE 3). The rotation flexibility designed into this articulation allows the correction of angular alignment deformity of up to 10°. The “ball/socket” design allows radio/capitellar contact through a functional range of flexion and forearm rotation for a spectrum of clinical presentations.

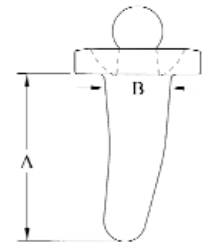
Radial Head Component

DIMENSIONS (mm)			
SIZE	CAT NO	A	B
2	RCN-II2	7.2	18.0
3	RCN-II3	10.2	21.0
4N	RCN-H4N	13.2	21.0
4	RCN-H4	13.2	24.0



Standard Stem Component

DIMENSIONS (mm)			
SIZE	CAT NO	A	B
2	RCN-S2	18.0	7.2
3	RCN-S3	20.0	8.0
4	RCN-S4	22.0	8.8



SURGICAL TECHNIQUE

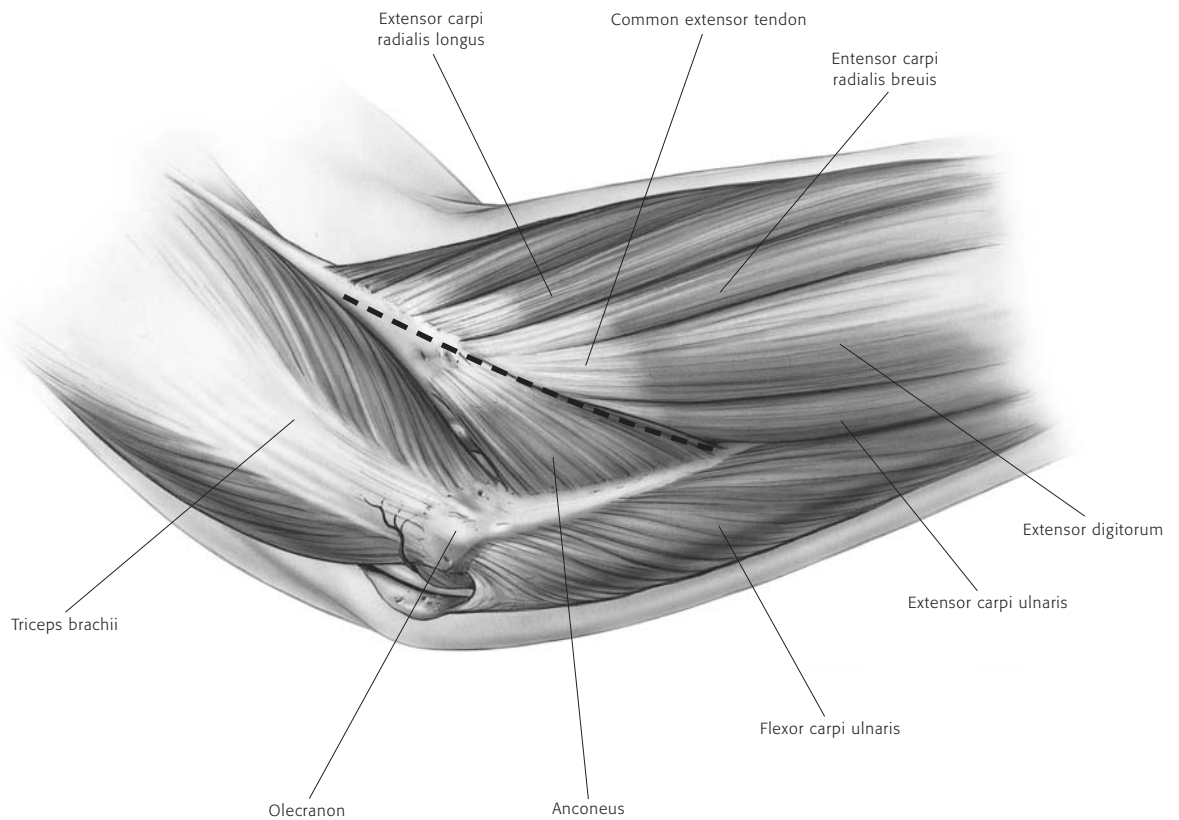
The Initial Incision



The patient is placed under a general or a regional anesthesia. The extremity is prepped and draped in the usual sterile fashion. A sterile tourniquet is often a good option. An arm table may be used if the patient is in a supine position or the arm may be brought across the chest.

The previous incision is re-entered, or a classic Kocher skin incision is made identifying the interval between the anconeus and the extensor carpi ulnaris (FIGURE 1). The incision extends approximately 6-7cm. The dissection is carried down to the joint capsule. The origin of the anconeus can be released subperiosteally and retracted posteriorly to permit adequate exposure of the capsule.

FIGURE 1



Capsular Exposure

2

If the elbow is stable, the capsule is exposed by elevating a portion of the extensor carpi ulnaris sufficiently to allow identification of the lateral collateral ligament complex (FIGURE 2A). Alternatively, the extensor carpi ulnaris may be split longitudinally in line with its fibers staying anterior to the attachment of the lateral collateral ligament. The lateral capsule is divided slightly anteriorly to the collateral ligament and the annular ligament and capsule are reflected anteriorly and posteriorly to expose the radial head.

A portion of the lateral collateral ligament and anterior capsule can be reflected off the lateral epicondyle and anterior humerus to expose the capitellum if necessary. The lateral ulnohumeral ligament must not be disturbed. If the ligament has been disrupted, then the exposure progresses through the site of disruption to expose the resected proximal radius. The common extensor tendon and elbow joint capsule are retracted as needed to maximize exposure (FIGURE 2B).

FIGURE 2A

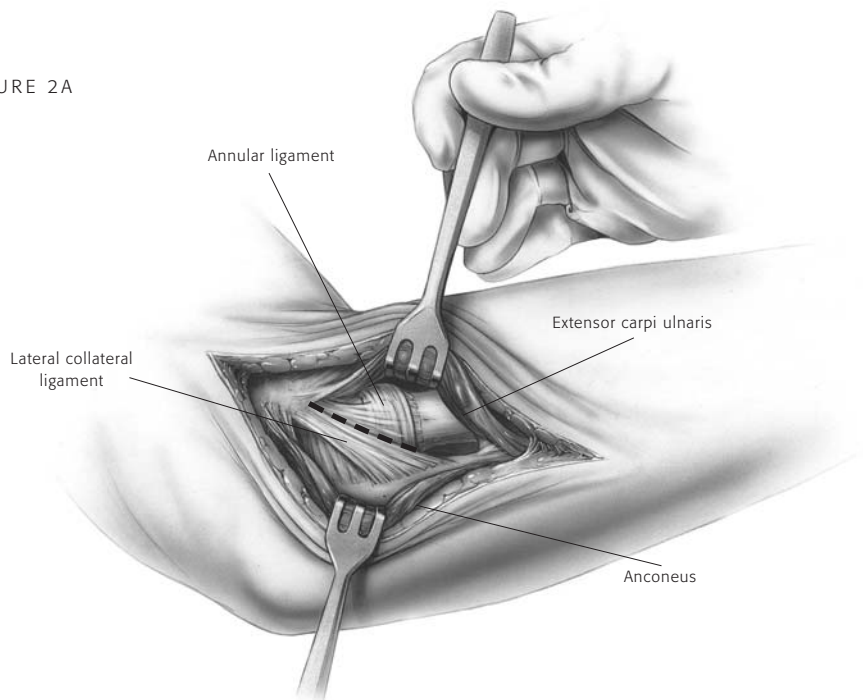
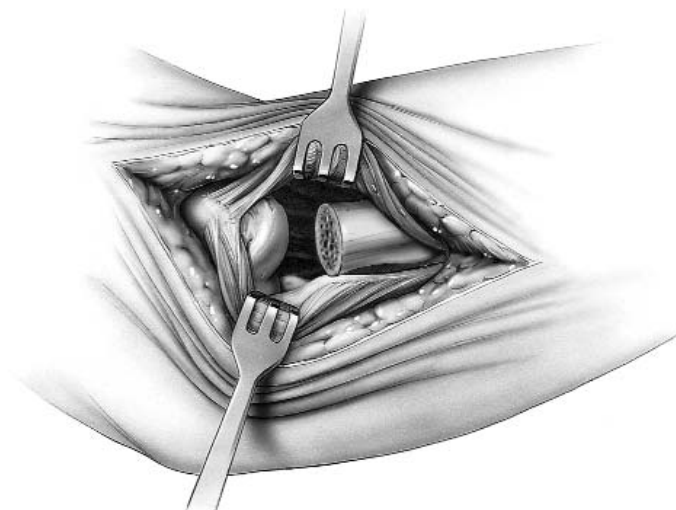


FIGURE 2B



Using the Radial Head Resection Guide

3

If sufficient bone is present, the radial neck is resected with a resection guide. The device is inserted over the capitellum with the axis of the alignment rod oriented over the ulnar styloid (FIGURE 3A). This alignment reflects the anatomic axis of forearm rotation. Test forearm rotation with the guide in place to ensure proper alignment. The proximal flange of the guide is placed against the articular surface of the capitellum and the rotating flange/alignment rod assembly is then guided proximally or distally to the desired length of radial shaft resection (FIGURE 3B).

Each notch on the threaded portion of the rod corresponds to a different head size. The rotating flange placement direction must be matched to the anticipated radial head implant size and the axis of forearm rotation. Once the desired length has been established, the proximal flange is secured by tightening the locking nut. The guide must be again aligned to the ulnar styloid (the axis of forearm rotation), not the radial shaft.

FIGURE 3A


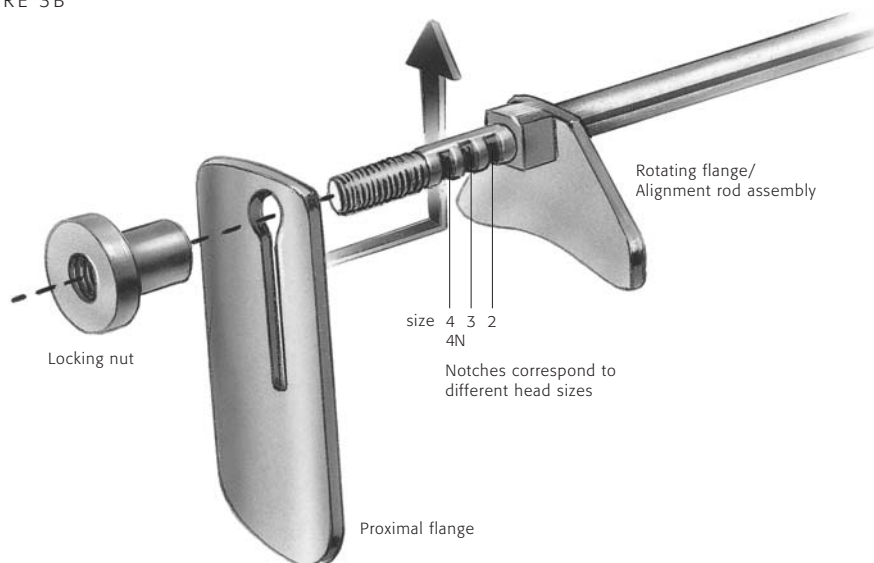


FIGURE 3B



Resecting the Radial Head

4

Using the resection guide, the blade should be guided by the distal surface of the rotating flange. During the resection, the forearm is pronated and supinated while the cutting guide is used to align the sawblade perpendicular to the axis of rotation (FIGURE 4A). Once initial alignment cuts have been made, the guide is removed and the resection is completed. The distal extent of resection is the minimal amount that is consistent with the restoration of function (FIGURE 4B). This includes at least the margin articulating with the ulna at the radial notch.

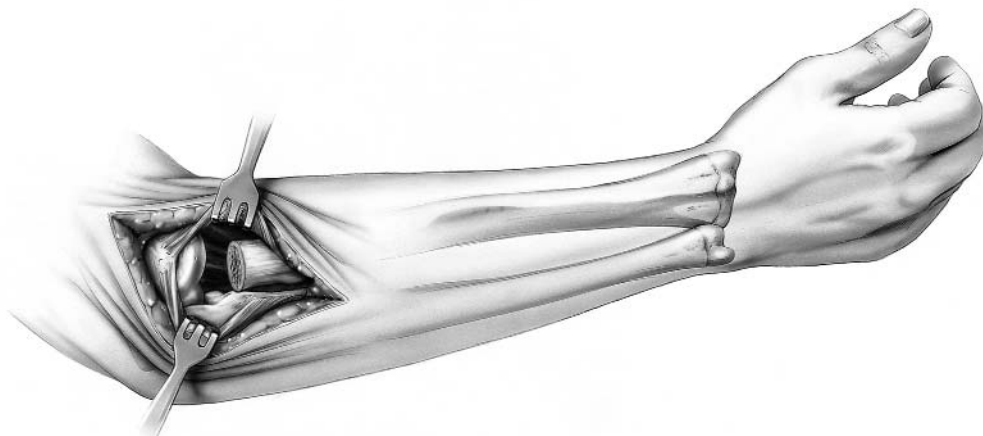
When the rHead_{RECON}[™] is to be used, after radial head resection was previously performed, the guide is employed to “freshen” the resected proximal radius. If the medullary canal is not obvious after the radius has been recut, a high speed bone burr is employed to identify the proximal radial canal.

In addition, radial length should be restored (axial traction) using a lamina spreader if there is a positive ulnar variance.

FIGURE 4A



FIGURE 4B



Intramedullary Preparation

5

If the elbow is unstable, varus stress and rotation of the forearm into supination allows improved access to the medullary canal. If the elbow is stable but the exposure is not adequate to access the medullary canal, careful reflection of the origin of the collateral ligament from the lateral epicondyle may be necessary to permit subluxation to the medullary canal. The canal is entered with a starter awl using a twisting motion (FIGURE 5A) or a high speed bone burr. The canal is then broached as allowed by the pathologic anatomy

of the proximal radius (FIGURE 5B). The curve of the broach should be directed away from the tuberosity (FIGURE 6). If the position of the tuberosity cannot be easily assessed, it generally is opposite to the radial styloid. Hence, the curve of the broach should be directed at the radial styloid. Ideally, the forearm should be in mid-rotation with the tuberosity directed posteriorly. Serial sized broaches are used until the broach fits snugly in the canal at the appropriate depth.

FIGURE 5A

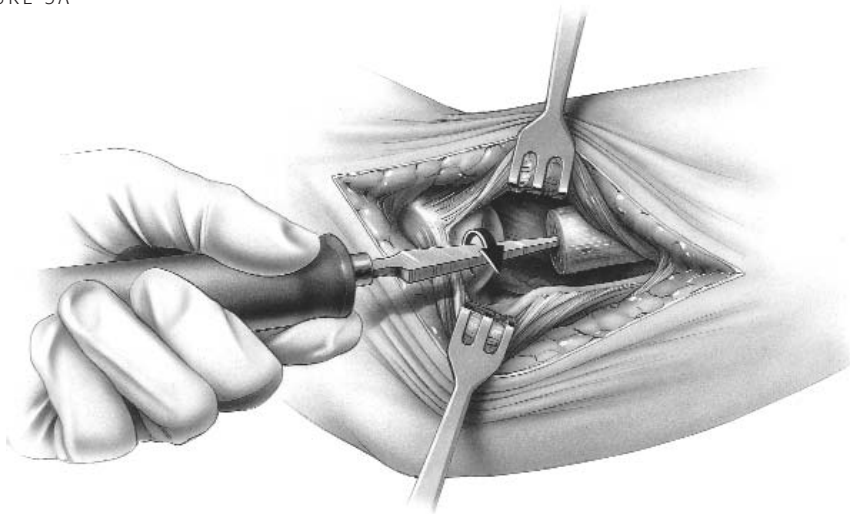
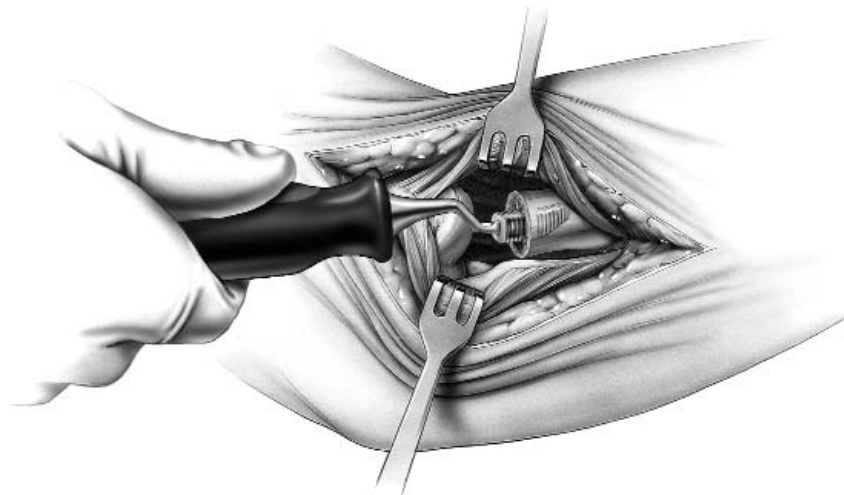


FIGURE 5B



Trial Stem Insertion

- 6 The appropriate sized trial stem is inserted in an arc-like fashion, facilitated by the curve of the stem. (FIGURE 6). Assure the collar is flush with the resection.

FIGURE 6

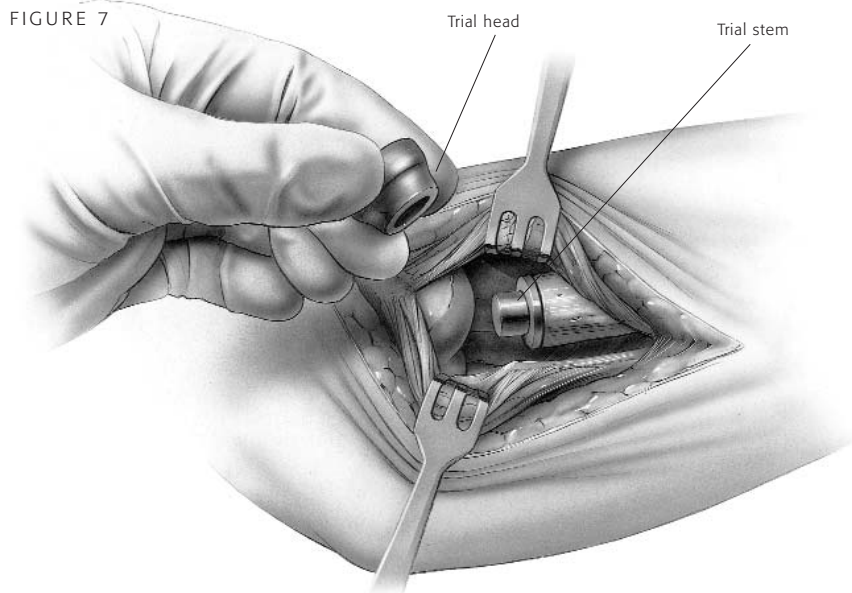


Trial Head Insertion

- 7 The trial head is attached to the trial stem (FIGURE 7), and tracking, both in flexion and extension and forearm rotation, should be carefully assessed. Malalignment of the osteotomy will cause abnormal tracking during flexion/extension and forearm pronation/supination.

NOTE In some instances adequate tracking cannot be attained. In this circumstance the implant should not be used.

FIGURE 7



Implanting the Final Components

8

Once acceptable alignment has been determined, the trials are removed and the permanent prosthesis is inserted in two steps. First, using the same arc-like motion as shown in FIGURE 6, the implant stem is placed in the medullary canal and tapped into place with the impactor (FIGURE 8A). If a firm fixation is not present at the time of the insertion of the trial stem (i.e. stem can be easily extracted from or rotated in the medullary canal), then bone cement (PMMA) is recommended. Second, the implant head of the prosthesis is assembled to the implant stem. This is accomplished by carefully placing the implant head into the jaws of the assembly tool and tighten the locking nut (FIGURE 8B). While applying longitudinal distraction and/or varus stress to distract the

radiocapitellar interface, insert the implant head between the capitellum and the spherical ball of the implant stem. Engage the lever of the assembly tool to the collar of the implant (FIGURE 8C). Using the assembly tool like a plier, snap the implant head onto the stem. Carefully remove the assembly tool to avoid damage to the implant. The elbow is then reduced (FIGURE 8D) and tested again in flexion/extension and pronation/supination.

NOTE Care should be taken to protect the articulating surfaces between the head and stem of any damage, including, but not limited to, scratches and contact with bone cement.

FIGURE 8A

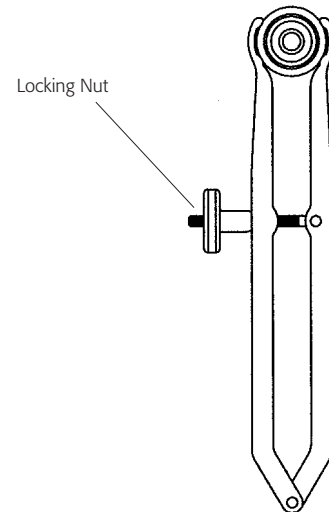
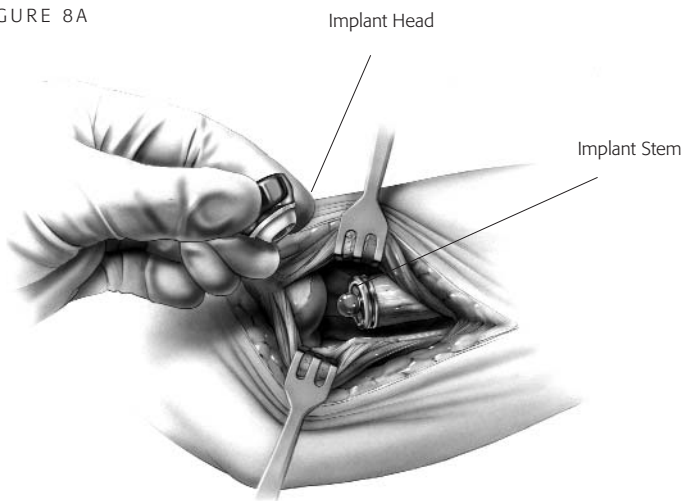


FIGURE 8B

FIGURE 8C

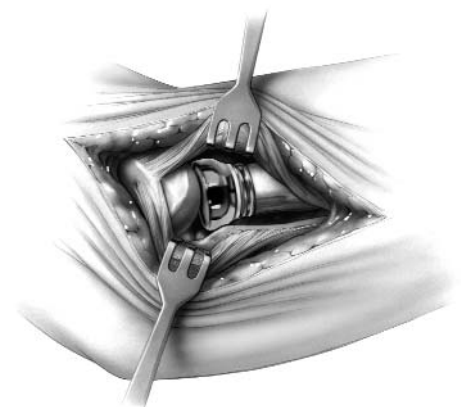
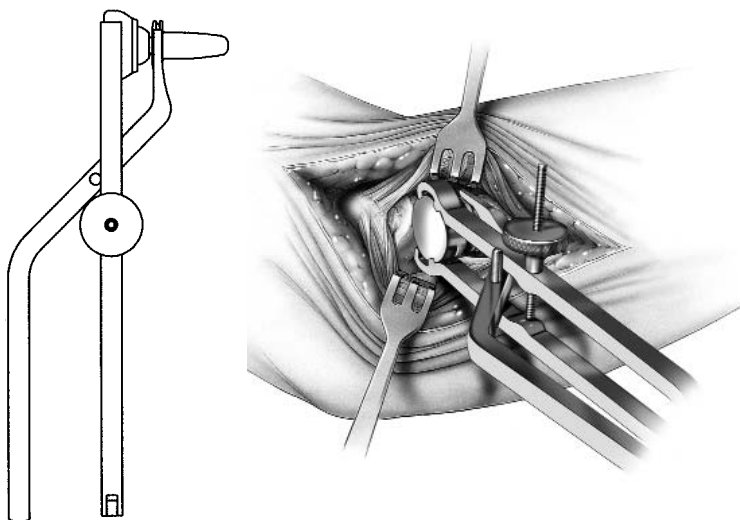


FIGURE 8D

Closure

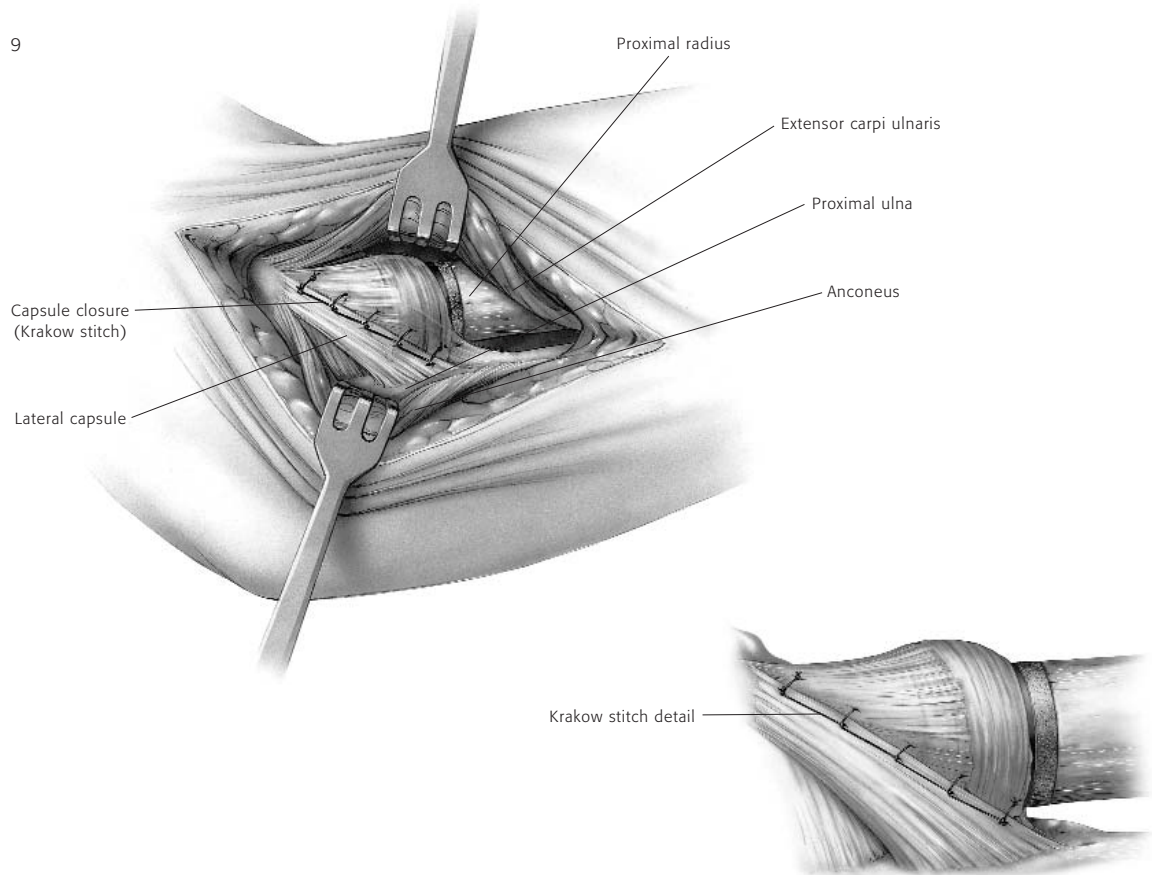
9

A simple closure is permitted if the collateral ligament is sufficient.

If the collateral ligament has been disrupted, a Krakow stitch is used. A No. 5 absorbable suture is placed distally, crossing the site of the lateral ulnar collateral ligament and is then brought proximally. Both ends of the suture are brought through a drill

hole at the anatomic origin of the lateral collateral ligament complex and exit posteriorly. The forearm is placed in full or partial pronation and the suture tied (FIGURE 9). The elbow is splinted at 90 degrees flexion and in neutral to full pronation. If ligamentous tissue is insufficient, a formal lateral collateral ligament reconstruction is done.

FIGURE 9



Aftercare

10

Passive flexion and extension is allowed on the second day assuming the elbow is considered stable. The goal of radial head replacement and soft tissue repair is to achieve elbow stability. Both flexion/extension and pronation/supination arcs are allowed without restriction. Active motion can begin by day five.

As with any prosthetic replacement, long

term aftercare requires surveillance. If the implant is asymptomatic and tracks well, routine removal is not necessary.

Indications for Use

Avanta Orthopaedics Radial Head implant is intended for replacement of the proximal end of the radius:

- Primary replacement after complex (comminuted) fracture of the radial head
- Symptomatic sequelae after radial resection
- Axial forearm instability
- Failed silicone radial head implant
- Elbow instability associated with radial head fracture or excision of radial head
- Replacement of the radial head for degenerative, or post-traumatic disabilities presenting pain, crepitation and decreased motion at the radiohumeral and/or proximal radio-ulnar joint.

Contraindications

- Bone musculature, tendons, or adjacent soft tissue compromised by disease, infection, or prior implantation which cannot provide adequate support or fixation for the prosthesis
- Any active or suspected infection in or around the joint
- Skeletal immaturity
- Physiologically or psychologically unsuitable patient
- Known sensitivity to materials used in this device
- Possibility for conservative treatment

Warnings

(See also the Patient Counseling Information Section)

- Strenuous loading, excessive mobility, and articular instability all may lead to accelerated wear and eventual failure by loosening, fracture, or dislocation of the device. Patients should be made aware of the increased potential for device failure if excessive demands are made upon it.
- Notification in accordance with the California Safe Drinking Water and Toxic Enforcement Act of 1986 (Proposition 65): This product contains a chemical(s) known to the State of California to cause cancer, and/or birth defects and other reproductive toxicity.

Precautions

- The implant is provided sterile in an undamaged package. If either the implant or the package appears damaged, expiration date has been exceeded, or if sterility is questioned for any reason, the implant should not be used. Do not resterilize.
- Meticulous preparation of the implant site and selection of the proper size implant increases the potential for a successful outcome.
- The implant should be removed from its sterile package only after the implant site has been prepared and properly sized.
- Implants should be handled with blunt instruments to avoid scratching, cutting or nicking the device so as not to adversely affect the implant performance. Polished bearing and articulating surfaces must not come in contact with hard or abrasive surfaces.
- The head and stem should not be implanted if the ball and socket features are possibly damaged, this includes repeated attaching and detaching.
- The head of the prosthesis is assembled on to the head of the stem. Prior to assembly confirm that the ball and socket features are dry and free from contaminant.

Patient Counseling Information

(See also Warnings)

In addition to the patient related information contained in the Warnings and Adverse Events sections, the following information should be conveyed to the patient.

- While the expected life of total joint replacement components is difficult to estimate, it is finite. These components are made of foreign materials which are placed within the body for the potential restoration of mobility or reduction of pain. However, due to the many biological, mechanical and physiochemical factors which affect these devices, the components cannot be expected to withstand the activity level and loads of normal healthy bone for an unlimited period of time.
- Adverse effects may necessitate reoperation, revision, or fusion of the involved joint.

Please refer to implant package insert for additional product information including precautions and warnings.

Surgical Video

For a surgical video of this product contact Avanta Orthopaedics.



9369A Carroll Park Drive, San Diego, CA 92121 858-452-8580 / 800-778-8837 / fax 858-452-9945

www.avanta.org © 2002 Avanta Orthopaedics 19-0387 rev.A